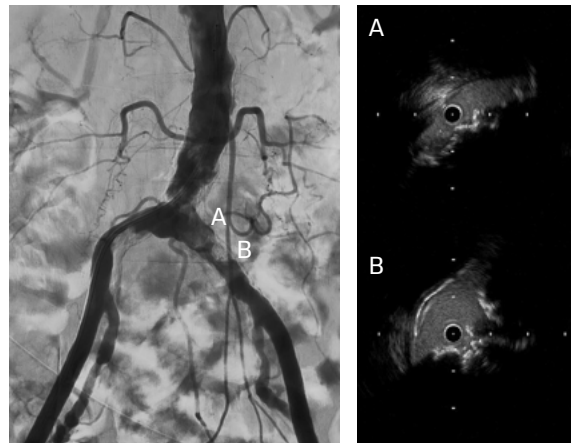


RESTORING FLOW TO A PATIENT WITH STENOSIS AT THE AORTOILIAC BIFURCATION

Case submitted by Masahiko Fujihara, M.D.

Challenge:

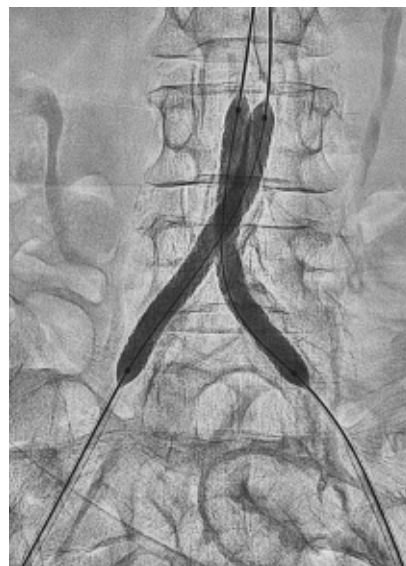
- 78-year-old female with severe intermittent claudication (Rutherford 3)
- Bilateral common iliac artery stenosis (TASC II D lesions) originating at the aortic bifurcation
- Relevant patient history:
 - Hypertension, hyperlipidemia, prior bilateral carotid artery stenosis



Calcified nodule at the aortoiliac bifurcation

Procedure:

- Gained bilateral access in the common femoral arteries
- Crossed lesions on both the left and right with .014" guidewires
- Dilated with a 2 mm diameter percutaneous transluminal angioplasty (PTA) balloon to allow for intravascular ultrasound examination
- Pre-dilation with 5 mm balloons in kissing balloon technique
- Exchanged to .035" stiff guidewires and 7 Fr long sheaths
- Deployed two 7 mm x 79 mm GORE® VIABAHN® VBX Balloon Expandable Devices (VBX Stent Graft) using kissing stent technique



GORE® VIABAHN® VBX Balloon Expandable Endoprosthesis deployment

Procedure (continued):

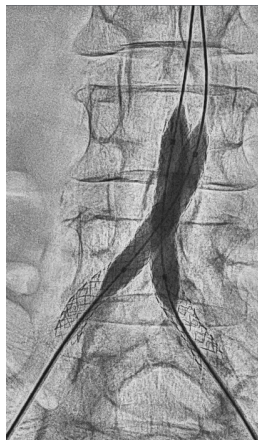
- Due to significant calcification, post-dilated first with two 8 mm x 40 mm PTA balloons
- Sequential post-dilation of VBX Stent Grafts proximally with a 10 mm x 20 mm PTA balloon followed by final post-dilation with kissing 8 mm x 40 mm PTA balloons
- Confirmed successful result using intravascular ultrasound and angiography

Result:

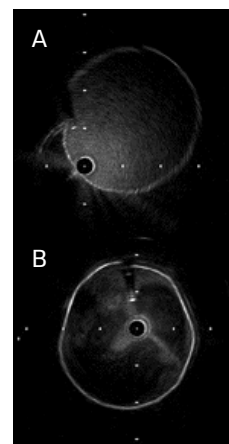
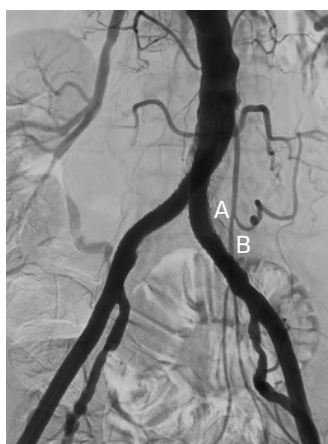- The patient was discharged with a full ankle-brachial index recovery and no remaining symptoms.

Case Takeaways

The VBX Stent Graft provides durable outcomes in highly calcified lesions. The performance of the VBX Stent Graft allows device customization to the anatomy (6–11 mm for 7 mm x 79 mm device) and provides radial strength to achieve luminal gain while potentially mitigating the risk of rupture and perforation.



Final post-dilation of the GORE® VIABAHN® VBX Balloon Expandable Endoprosthesis



Fully expanded GORE® VIABAHN® VBX Balloon Expandable Endoprosthesis across the calcified segment

Images courtesy of Masahiko Fujihara, M.D. Used with permission.

Consult Instructions
for Use
eifu.goremedical.com

INDICATIONS FOR USE IN THE U.S.: The GORE® VIABAHN® VBX Balloon Expandable Endoprosthesis is indicated for the treatment of de novo or restenotic lesions found in iliac arteries with reference vessel diameters ranging from 5 mm–13 mm and lesion lengths up to 110 mm, including lesions at the aortic bifurcation. **CONTRAINDICATIONS:** Do not use the GORE® VIABAHN® VBX Balloon Expandable Endoprosthesis in patients with known hypersensitivity to heparin, including those patients who have had a previous incident of Heparin-Induced Thrombocytopenia (HIT) type II. Refer to *Instructions for Use* at eifu.goremedical.com for a complete description of all applicable indications, warnings, precautions and contraindications for the markets where this product is available. ^{Rx only}

The outcomes and observations reported are based on individual case experience and the patients treated. The steps described here may not be complete, and are not intended to be a replacement for the *Instructions for Use* or the education, training and professional judgment of healthcare providers (HCP). HCPs remain solely responsible for making decisions about patient care and the use of medical technologies.

Products listed may not be available in all markets.

GORE, *Together, improving life*, VBX, VIABAHN and designs are trademarks of W. L. Gore & Associates.
© 2021 W. L. Gore & Associates, Inc. 2188252-EN APRIL 2021

W. L. Gore & Associates
goremedical.com

Asia Pacific +65 67332882 Australia/New Zealand 1800 680 424 Europe 00800 6334 4673
United States Flagstaff, AZ 86004 800 437 8181 928 779 2771

