

# CASE REVIEW

Successful relief of biliary obstruction with  
normalization of serum bilirubin

Case submitted by Todd H. Baron, M.D.  
Chapel Hill, North Carolina



**GORE® VIABIL®**  
Biliary Endoprosthesis

## CASE TAKEAWAYS



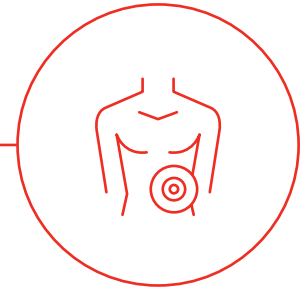
**This case illustrates the benefits of important design features in a clinical setting:**

- The lack of foreshortening (*Figure 1*) of the device enabled placement of the stent precisely with the proximal end below the bifurcation:
  - Prior surgical resection left little room below the biliary bifurcation, with the short residual common hepatic duct anastomosed to the jejunum.
  - This prevented obstruction of one side of the biliary tree.
- Secondly, the stent can be passed through a longer length smaller channel endoscope (pediatric colonoscope).

*Figure 1:* GORE® VIABIL® Biliary Endoprosthesis

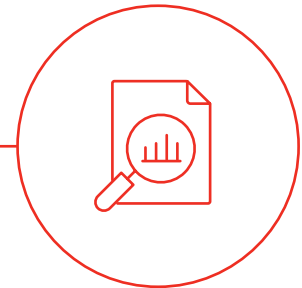

## PATIENT CHARACTERISTICS



- **Patient gender:** Female
- **Patient age:** 66
- **Patient condition(s)/diagnosis:** Adenocarcinoma of the pancreatic head cancer
- **Patient revisions/history:** Whipple operation (pancreaticoduodenectomy)

## CASE DETAILS



- **Presenting issue:** Malignant biliary obstruction in the setting of post-surgical anatomy.
- **Description of treatment approach:** An endoscopic retrograde cholangiopancreatography (ERCP) was initially attempted with a small caliber colonoscope (pediatric colonoscope), however there was an obstruction.

The endoscope was passed into the afferent limb, but the biliary anastomosis (hepaticojejunostomy) was obstructed. Endoscopic Ultrasound-guided Rendezvous (EUS-RV) technique was performed using a therapeutic channel linear echoendoscope initially to view the obstruction.

The left hepatic duct was punctured with a standard 19 gauge BOSTON SCIENTIFIC EXPECT SLIMLINE (SL) EUS Aspiration Needle and a cholangiogram showed obstruction of the common hepatic duct (*Figure 2*).

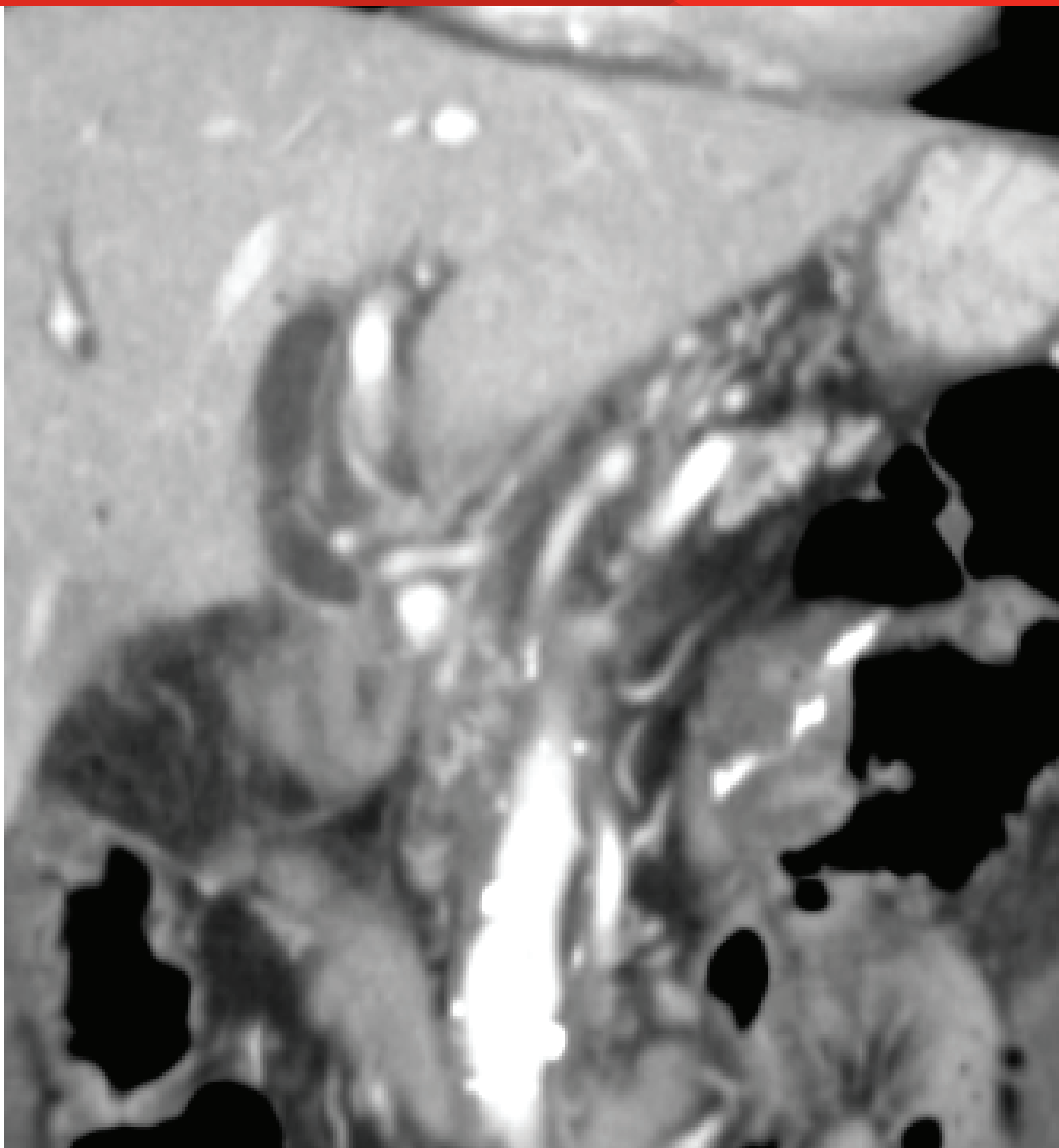
---

**Figure 2:** Coronal computed tomography (CT) prior to endoscopic intervention showing dilated biliary tree with obstruction at the hepaticojejunostomy by soft tissue mass.

---

**Image courtesy of Todd H. Baron, M.D.  
Used with permission.**

BOSTON SCIENTIFIC, EXPECT and SLIMLINE are trademarks of Boston Scientific Corporation.



An OLYMPUS® VISIGLIDE Guidewire 450 cm long was passed antegrade into the biliary tree, across the hepaticojejunostomy and into the jejunum (*Figure 3*).

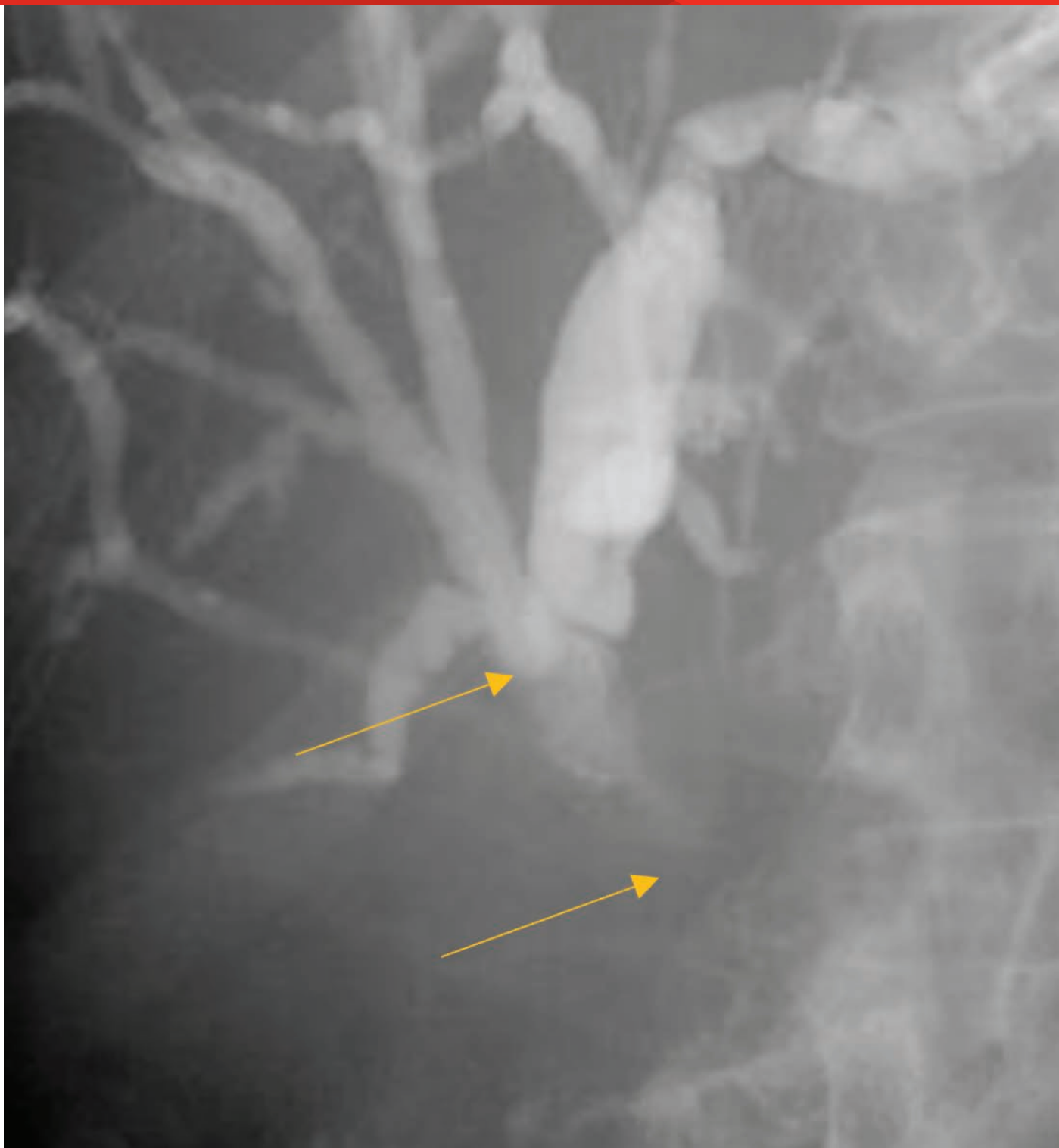
---

**Figure 3:** Radiographic image showing echoendoscope in the stomach with injection via 19 gauge endoscopic ultrasound aspiration needle after puncture of the left hepatic duct. Cholangiogram shows dilated intrahepatic duct with obstruction at the hepaticojejunostomy. The top arrow points to the bifurcation. Bottom arrow points at the upper margin of stricture.

---

**Image courtesy of Todd H. Baron, M.D. Used with permission.**

OLYMPUS and VISIGLIDE are trademarks of Olympus Corporation.



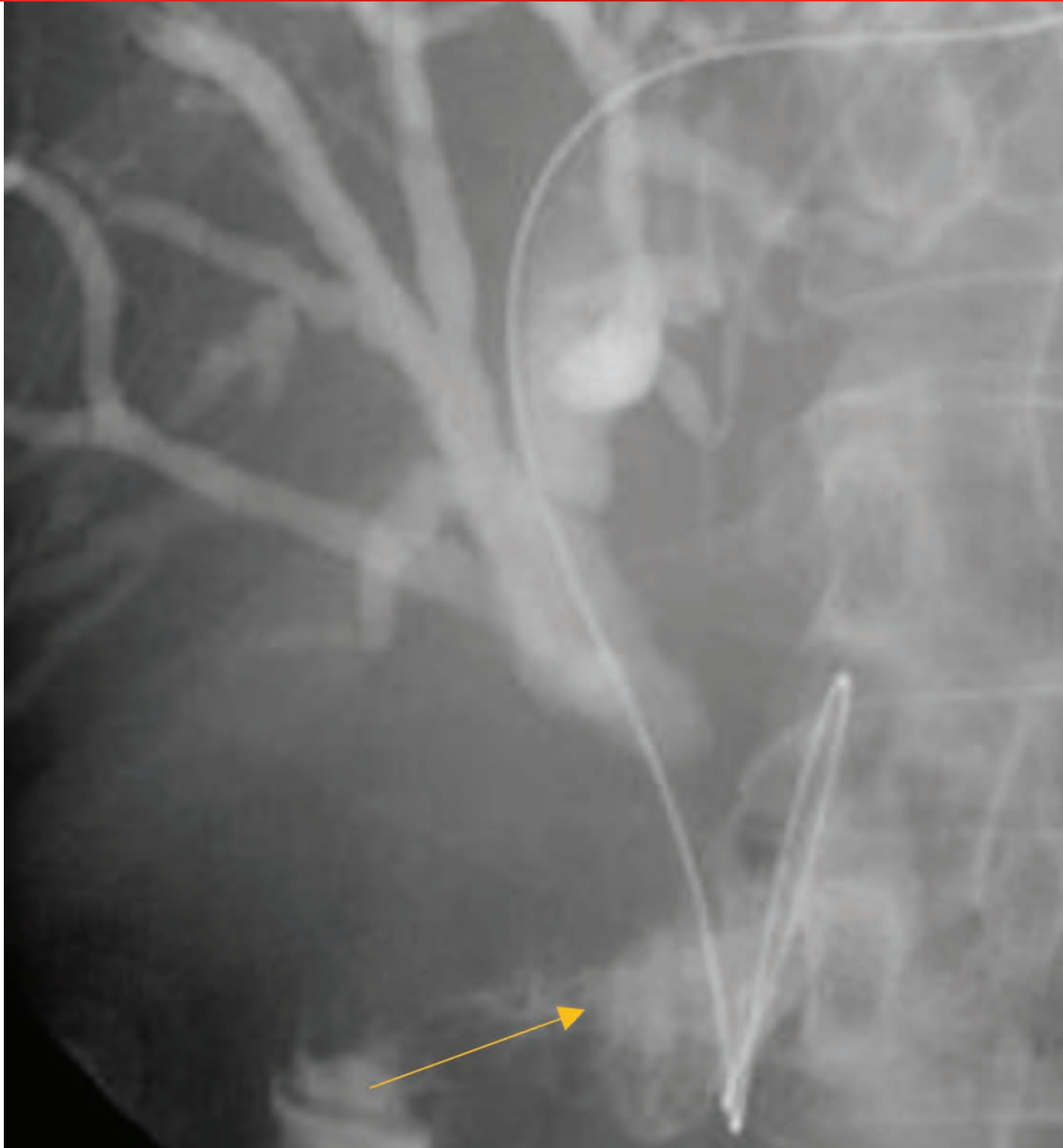The forward viewing endoscope was reintroduced and the guidewire was grasped and withdrawn through the endoscope (*Figure 4*).

---

**Figure 4:** Radiographic image showing the guidewire passed through the needle across the hepaticojeunostomy into the jejunum. The arrow points to the contrast in jejunum.

---

Image courtesy of Todd H. Baron, M.D.  
Used with permission.



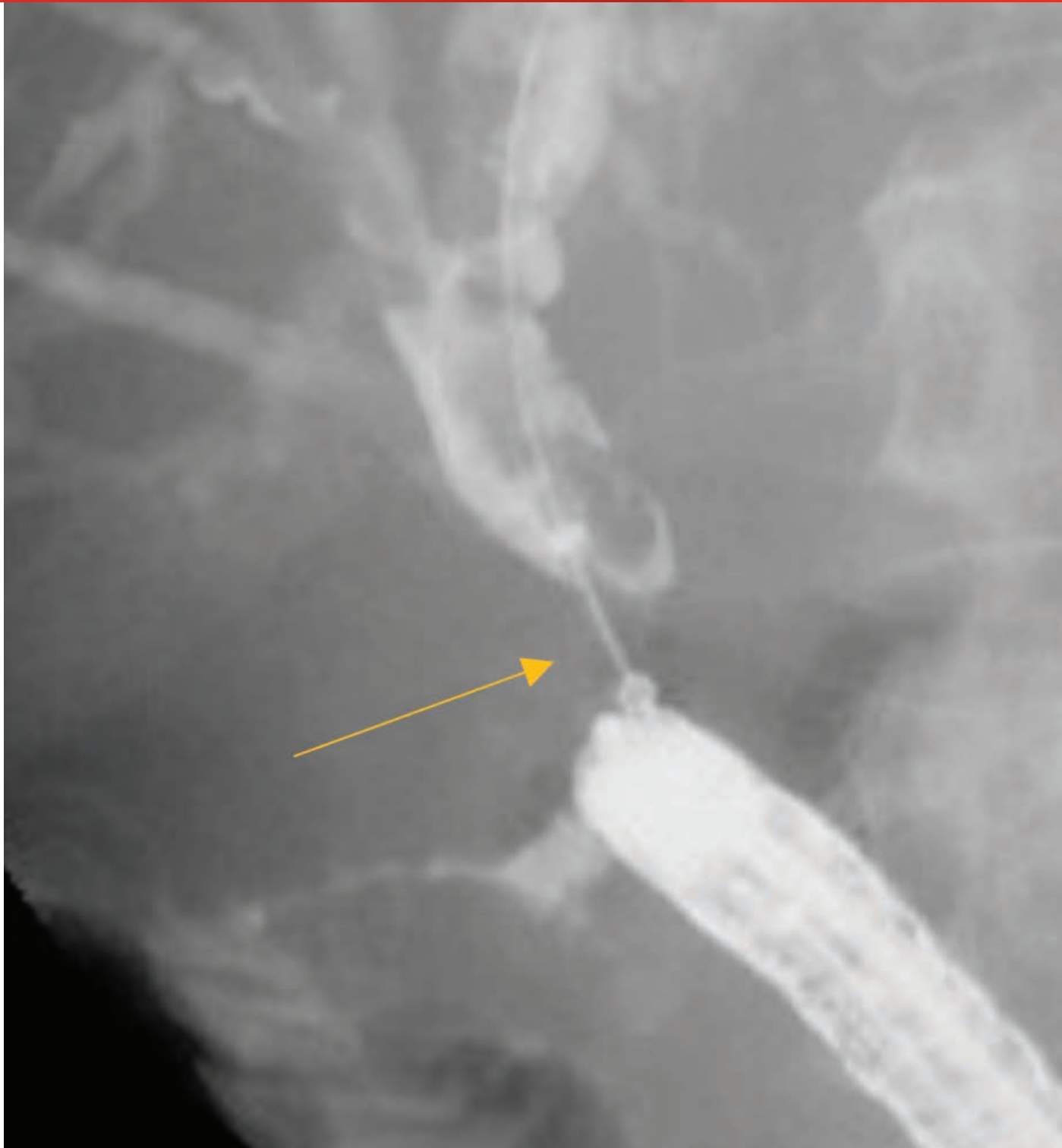
Over the guidewire a 10 mm diameter X 4 cm length GORE® VIABIL® Biliary Endoprosthesis was placed via ERCP with the proximal end just below the biliary bifurcation (*Figures 5 and 6*) and the distal end in the duodenum (*Figure 7*).

---

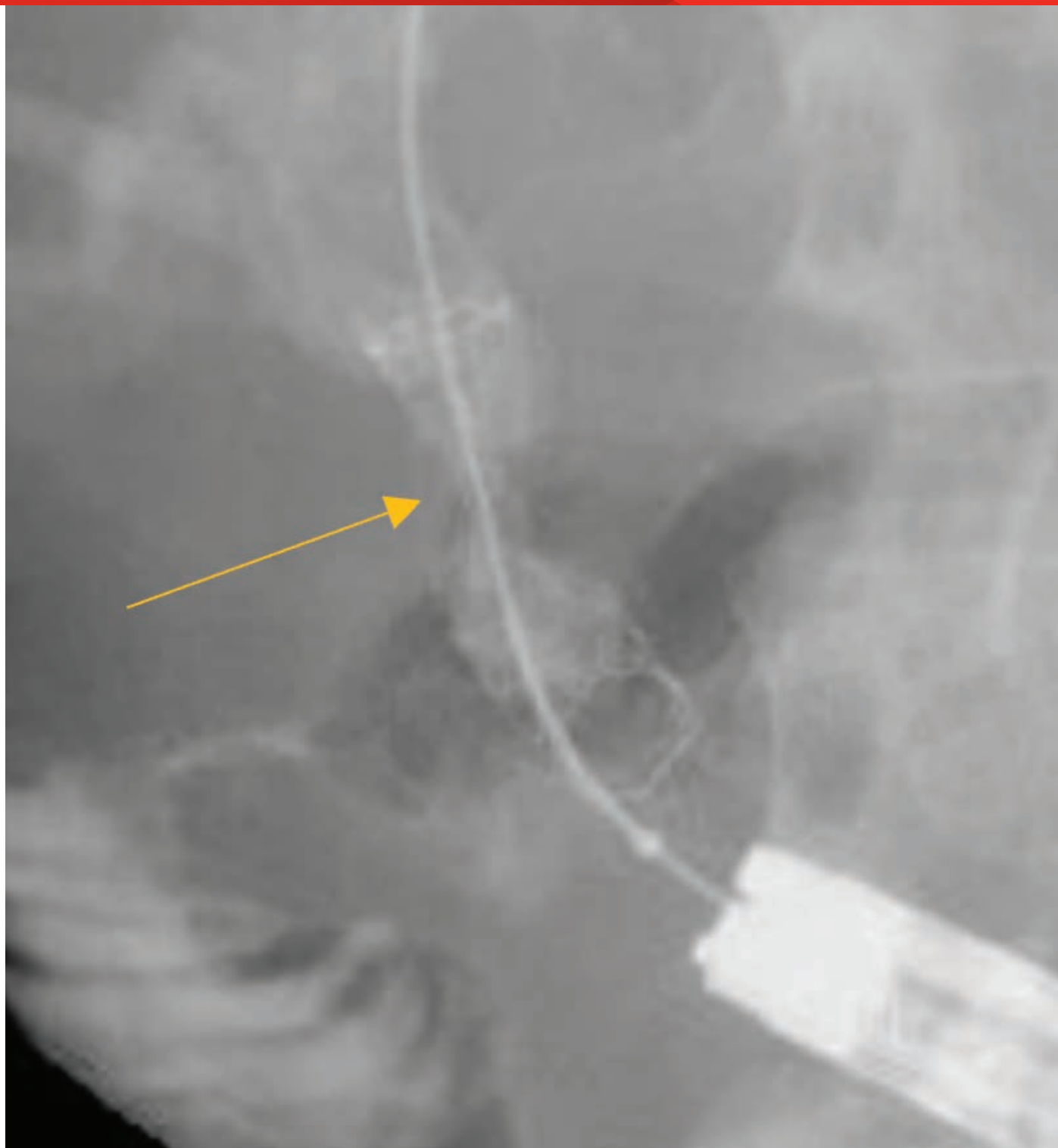
**Figure 5:** Radiographic image showing forward-viewing endoscope positioned in the jejunum with guidewire grasped. The arrow points at midpoint of stricture.

---

Image courtesy of Todd H. Baron, M.D.  
Used with permission.



Over the guidewire a 10 mm diameter X 4 cm length GORE® VIABIL® Biliary Endoprosthesis was placed via ERCP with the proximal end just below the biliary bifurcation (*Figures 5 and 6*) and the distal end in the duodenum (*Figure 7*).



---

**Figure 6:** Radiographic image showing GORE® VIABIL® Biliary Endoprosthesis in place immediately after deployment. A waist is seen in the center of the stent at the point of stricture. The arrow points to the stent waist.

---

Image courtesy of Todd H. Baron, M.D.  
Used with permission.



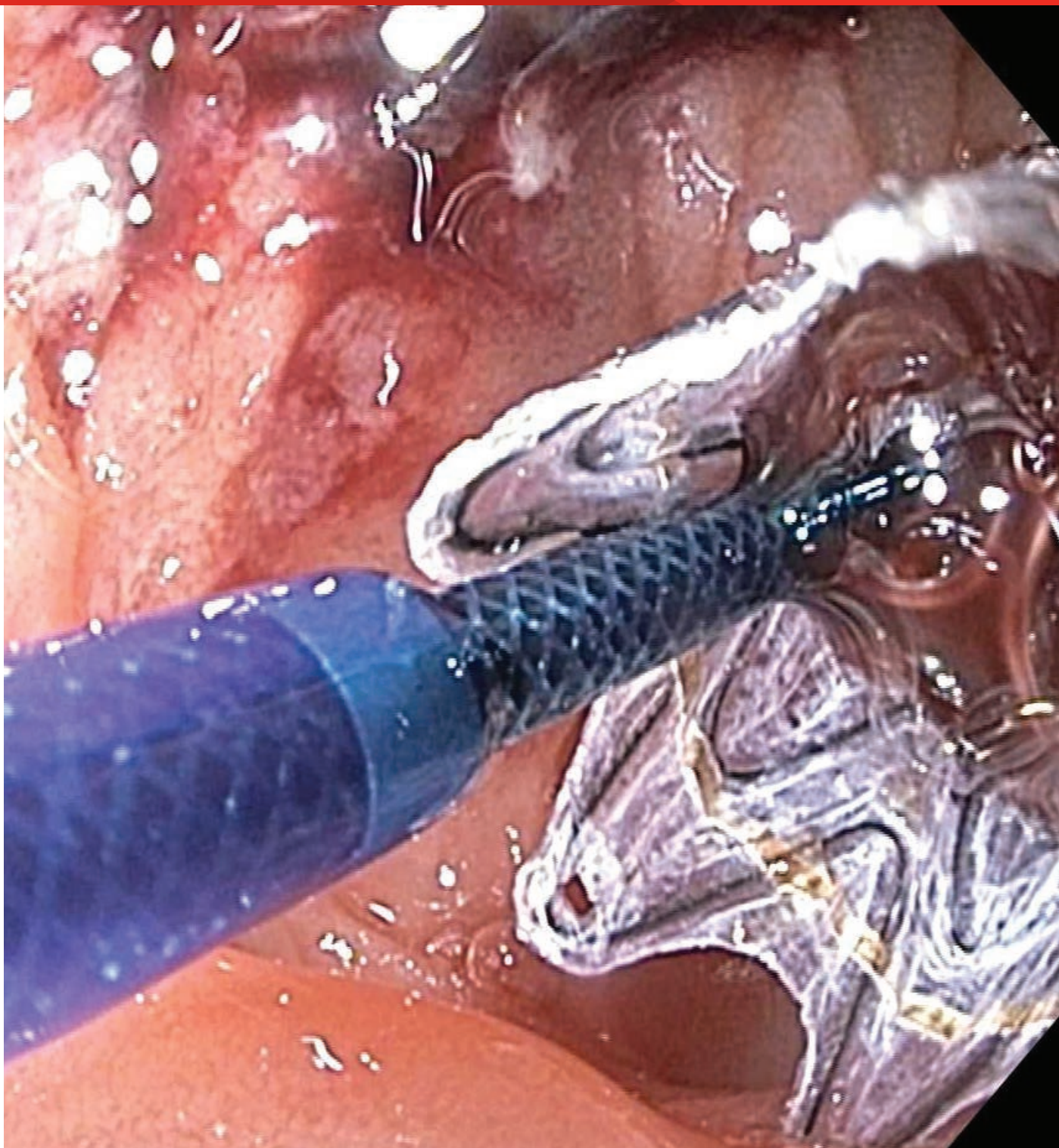
Over the guidewire a 10 mm diameter X 4 cm length GORE® VIABIL® Biliary Endoprosthesis was placed via ERCP with the proximal end just below the biliary bifurcation (*Figures 5 and 6*) and the distal end in the duodenum (*Figure 7*).

---

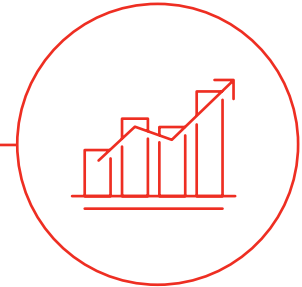
**Figure 7:** Endoscopic image of GORE® VIABIL® Biliary Endoprosthesis immediately upon deployment with endoscope positioned in the jejunum, just distal to the hepaticojejunostomy.

---

Image courtesy of Todd H. Baron, M.D.  
Used with permission.



## RESULTS



- **Post treatment outcome:** Successful relief of biliary obstruction with normalization of serum bilirubin.
- **Follow-up:** Two months post-procedure the serum bilirubin remained normal. However, the patient died later due to complications from the progressive malignant disease.

The outcomes and observations reported are based on individual case experience and the patients treated. The steps described here may not be completed and are not intended to be a replacement for the *Instructions for Use* or the education, training and professional judgment of healthcare providers (HCP). HCP remain solely responsible for making decisions about patient care and the use of medical technologies.



**Authorized Distributor**  
of Gore Medical Products

 Consult Instructions  
for Use  
[eifu.goremedical.com](https://eifu.goremedical.com)

Refer to *Instructions for Use* at [eifu.goremedical.com](https://eifu.goremedical.com) for a complete description of all applicable indications, warnings, precautions and contraindications for the markets where this product is available.  $\text{Rx}$  only

Products listed may not be available in all markets.

BOSTON SCIENTIFIC, EXPECT and SLIMLINE are trademarks of Boston Scientific Corporation.

OLYMPUS and VISIGLIDE are trademarks of Olympus Corporation.

CONMED and designs are trademarks of CONMED Corporation.

GORE, *Together, improving life*, VIABIL and designs are trademarks of W. L. Gore & Associates.

© 2022, 2023 W. L. Gore & Associates, Inc. 23871351-EN FEBRUARY 2023

---

**W. L. Gore & Associates, Inc.**  
goremedical.com

**Asia Pacific** +65 6733 2882 **Australia/New Zealand** 1800 680 424 **Europe** 00800 6334 4673

**United States** Flagstaff, AZ 86003 800 437 8181 928 779 2771

