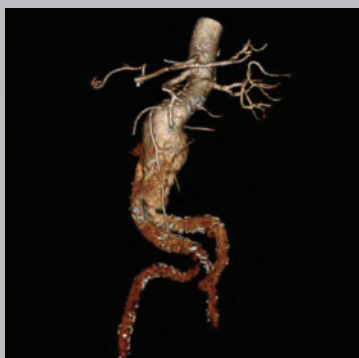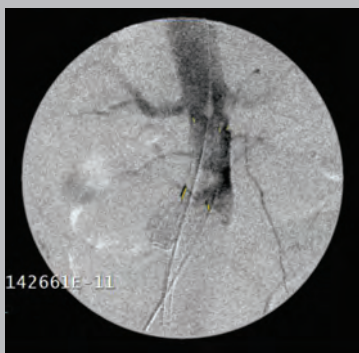


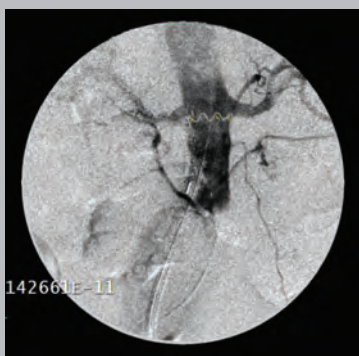
# Endovascular Repair of an Abdominal Aortic Aneurysm



**Figure 1.**  
Initial CT angiogram.



**Figure 2.**  
Initial deployment.



**Figure 3.**  
Final deployment after marker alignment and repositioning.

**Stefano Bonardelli, MD**  
Department of Surgery, University of Brescia  
Brescia, Italy

**Giuseppe Battaglia, MD**  
Institute of Radiology, University of Brescia  
Brescia, Italy

## INTRODUCTION

An 82-year-old man was admitted to general surgery for abdominal pain. He presented with hypertension, atrial fibrillation (on oral anticoagulation therapy), and Parkinson's disease. In the past he suffered a stroke and pulmonary embolism. He was subjected to an abdominal ultrasound, which revealed the presence of an infrarenal abdominal aortic aneurysm with a diameter of approximately 7 cm. The patient then underwent an urgent CT scan that confirmed the presence of a large infrarenal aortic aneurysm of 83 mm with radiological signs of impending rupture. The aortic neck measured 20–22 mm in diameter, with anteroposterior angulation of 43° and laterolateral angulation of 51°. The left internal iliac artery presented an aneurysm and was occluded a few millimeters distal to the iliac bifurcation (*Figure 1*).

## PROCEDURE

After surgical isolation of the common femoral arteries, the main prosthetic body (GORE® EXCLUDER® AAA Endoprosthesis featuring C3® Delivery System, 26 x 14 x 14) was introduced from the left side and was deployed below the right renal artery. The C-arm was rotated in the anteroposterior direction to align the three proximal radiopaque markers in order to correct for the parallax effect.



PERFORMANCE  
through experience

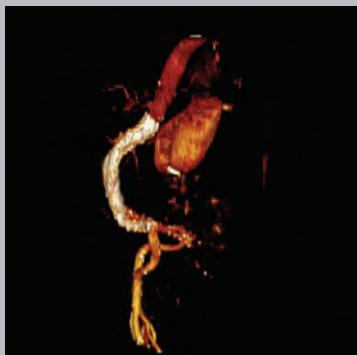


Figure 4.  
Final CT angiogram.

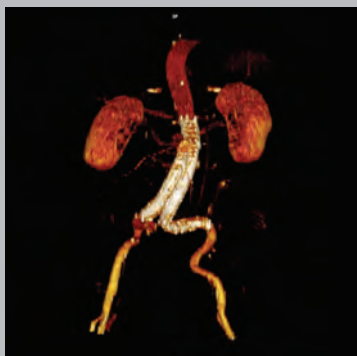

Figure 5.  
Final CT angiogram.

The device was then repositioned proximally to align with the right renal artery ostium and optimize proximal landing. The procedure was completed by introducing the right contralateral leg (20 x 14) and an iliac extender (14 x 14). This was followed by proximal and distal ballooning (*Figure 2 and 3*).

## RESULTS

Completion angiography showed the complete exclusion of the aneurysm and the absence of an endoleak. A postoperative CT scan confirmed the optimal success of the procedure, with complete exclusion of aneurysm sac and the absence of an endoleak (*Figure 4 and 5*).

## CONCLUSION

The innovative GORE® C3® Delivery System provides the clinician with the ability to reposition the GORE® EXCLUDER® Device prior to final release from the delivery catheter. This feature may minimize complications that could occur if the graft needs to be repositioned after the initial deployment; therefore, this system is safe and reliable in complex anatomies.



### W. L. GORE & ASSOCIATES, INC.

Flagstaff, AZ 86004

+65.67332882 (Asia Pacific)

00800.6334.4673 (Europe)

800.437.8181 (United States)

928.779.2771 (United States)

[goremedical.com](http://goremedical.com)

Products listed may not be available in all markets.

GORE®, C3®, EXCLUDER®, PERFORMANCE THROUGH EXPERIENCE, and designs are trademarks of W. L. Gore & Associates.  
© 2013 W. L. Gore & Associates, Inc. AS1064-EN1 AUGUST 2013