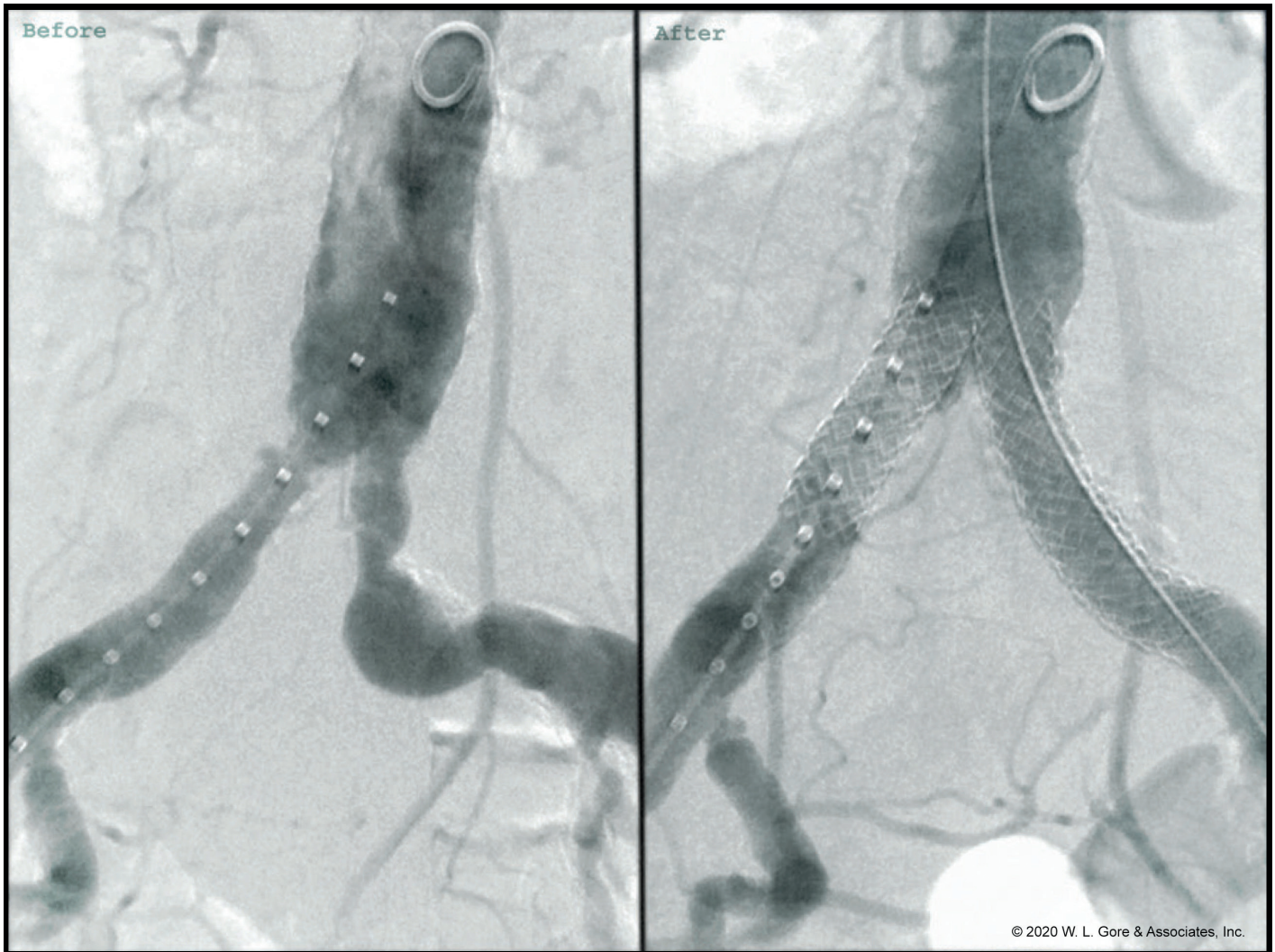



## Innovative solutions for the treatment of complex aorto-iliac occlusive disease

# Endovascular reconstruction of the aortic bifurcation

**Michele Antonello** considers the complexity of aortoiliac occlusive disease, treatment gaps and current options.

TASC C AND D LESIONS, THE subgroup of lesions involving the aortic bifurcation, represent a challenging situation. The traditional endovascular approach in these cases is the kissing stents technique, which is associated with an excellent technical success rate, a low medical and surgical complication rate, and satisfactory long-term primary patency rates (81% at 24 months and 69% after five years). Some anatomical characteristics of the aortic bifurcation may be responsible for an inadequate reconstruction. Moreover, there is not clear evidence on the best type of stent to be used in the kissing configuration. Some *in vitro* and *in vivo* studies suggest that, to optimise haemodynamics and improve long-term outcomes, the ideal stent to be used in the kissing conformation should allow a precise symmetric protrusion in the infrarenal aorta, optimal conformability, and apposition between the stents and the aortic wall.

The GORE® VIABAHN® VBX Balloon Expandable Endoprosthesis (VBX Stent Graft) is a novel heparin-bonded covered stent approved for the treatment of peripheral arteries. The use of this stent, due to its high conformability and capability to flare the stent's edges to different diameters, may represent a valid option for the endovascular reconstruction of the aortic bifurcation.

A key consideration in this scenario is the use of two VBX Stent Grafts with the same diameter. These have to be deployed simultaneously, protruding into the infrarenal

aorta for approximately 1.5 – 2 cm. Post-dilatation of the stents is performed in a kissing fashion using two 12 x 20 mm compliant balloons (CORDIS® Powerflex® Pro PTA) inflated at the same time. This allowed an appropriate apposition between the stents and the aortic wall avoiding any “dead space” that may be responsible for blood flow perturbations, thrombus formation and intimal hyperplasia. In our experience, the use of the 8 mm diameter “8L” device was particularly useful, and has become the preferred choice (57% of cases) to perform the kissing stents technique, as it allows post-dilatation to a wide range of measurements from 8 – 16 mm. This tip helps to avoid technical problems related to diameter mismatch between the infrarenal aorta and the CIAs and allows the kissing stents to optimally adapt to conical or enlarged distal aortas.

## The “VERAB” technique

Another endovascular approach to aortic reconstruction is the CERAB technique, which, in aorto-iliac disease, has been well described for the treatment of complex aorto-iliac disease involving the distal portion of the infrarenal aorta. It consists of deployment of a balloon-expandable covered stent 15 – 20 mm above the aortic bifurcation, proximally adapted to the aortic

wall with a large balloon, creating a cone-shaped stent. Two iliac balloon expandable covered stents are then placed in the distal conic segment and simultaneously inflated, making a tight connection with the aortic cuff, that simulates a new aortic bifurcation. Recent *in vitro* studies have demonstrated that some geometric features of the CERAB may affect haemodynamics with possible influences on long-term outcomes. An asymmetric protrusion of the two parallel stents and a non-ideal apposition between the parallel grafts and the aortic stent may cause turbulence and / or stasis of blood flow, that can be responsible, in the future, for thrombus formation and intimal hyperplasia. In this setting, the use of the VBX Stent Graft (“VERAB” technique) may overcome these problems. In our experience usually a 11 x 79 mm or 59 mm VBX Stent Graft was deployed in the aorta, moulded with a non-compliant balloon to reach the diameter of the aorta and subsequently two 8 L / 59 or 79 mm VBX Stent Graft released in kissing protruding in

the previously aortic stent. The final step of the procedure is to perform the molding of the kissing stent using two 12 mm compliant balloons as previously described. This allows conformity of the stents, achieving a complete apposition of the iliac stents to the aortic one, eliminating the risk of gutters (Figure 2).

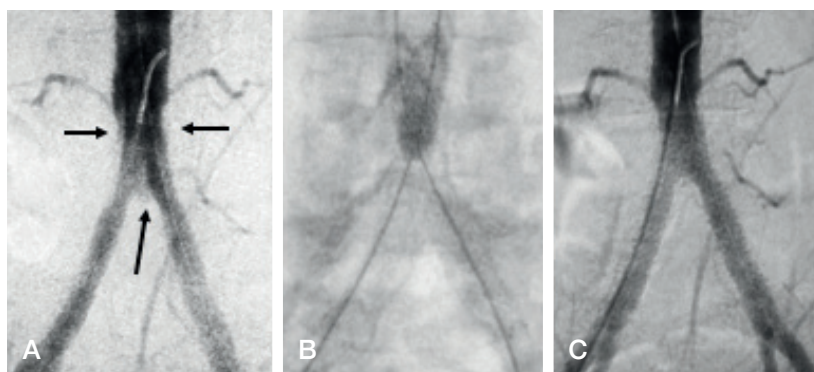
In conclusion, the VBX Stent Graft is a new tool that seems to fill some important gaps in the endovascular treatment of aorto-iliac disease.

*Michele Antonello is a vascular surgeon at Padua University, Padua, Italy.*

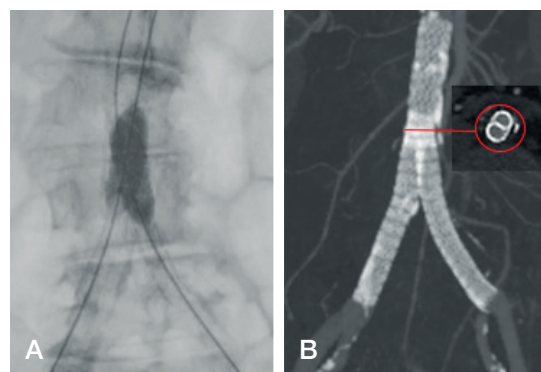
References for this article can be found online at [www.vascularnews.com](http://www.vascularnews.com)



**Michele Antonello**



**Fig. 1:** Shows the presence of gutters after GORE® VIABAHN® VBX Balloon Expandable Endoprosthesis deployment (A), that disappeared (C) after post-dilatation using two compliant balloons (B).



**Fig. 2** Postoperative angio-CT showing the perfect apposition between the kissing stents with the aortic one (B), after post dilatation with two compliant balloons (A).



# Results from the VBX FLEX study

**Jean Bismuth** discusses results from the VBX FLEX study, considering the technical success of the data in comparison to both the ICARUS and BOLSTER trials.

IN THE USA, BALLOON EXPANDABLE covered stents have long been limited to the ATRIUM® iCAST® Covered Stent, but we have in the last few years seen the release of the GORE® VIABAHN® VBX Balloon Expandable Endoprosthesis (VBX Stent Graft) and the BD® LIFESTREAM® Balloon Expandable Vascular Covered Stent. The motivation to enter the market with such devices is likely prompted by the compelling data supporting the use of balloon expandable stent grafts in the treatment of complex aorto-iliac occlusive disease. The COBEST trial, a randomised trial between bare metal stents and the Advanta V12, established that the Advanta V12 achieved better results than bare metal stents for TransAtlantic InterSociety (TASC) Consensus C and D lesions. Additionally, for TASC C and D lesions, improved long-term patency as well as clinical outcomes was achieved with the Advanta V12. This was far from the only study demonstrating the benefit of covered stents in the management of aorto-iliac occlusive disease, with Chang *et al* reporting patency rates at five years of 87% ± 5% vs. 53% ± 7%;  $P < 0.01$  for covered versus bare metal stents respectively. Sabri *et al* also compared bilateral covered stent use to bare-metal stent placement in a “kissing” configuration at the aortic bifurcation, revealing superior patency for covered stents at two years (92% vs. 62%;  $P = 0.023$ ). The use of covered stents in complex iliac lesions is further supported by the Society for Vascular Surgery Lower Extremity Guidelines Writing Group in their recommendations.

The number of aorto-bifemoral bypass procedures for occlusive disease performed by vascular surgery trainees has, surprisingly, not declined despite a significant increase in total procedures performed for aorto-iliac disease. Of course, the increase in procedures is primarily driven by endovascular cases. Given the fact that we are seeing a greater number of vascular surgeons who are well-trained interventionists, it is natural that the demands on devices, which can further our ability to manage complex disease is essential. Therefore, it is important to critically review available devices. Despite



Jean Bismuth

to overcome some of the difficulties encountered with standard devices, namely conformability, stent retention, deliverability and foreshortening. Although, all three stents are composed of stainless steel and PTFE, that is essentially where the similarities end. The VBX Stent Graft is designed with independent stainless steel rings, which solves a number of the aforementioned issues, conformability, deliverability and stent foreshortening. Conformability becomes very important when tackling the external iliac artery, because there is substantial longitudinal compression in this vessel. In the

falling into the same category of a balloon expandable covered stents, there are important engineering features, trial implications and overall results that differentiate the three products currently on the US market.

The VBX Stent Graft was designed

**“The VBX Stent Graft is an efficacious tool in the management of aortoiliac occlusive disease.”**

VBX FLEX study there was no statistically significant difference in outcomes in patients who had their external iliac artery treated with the VBX Stent Graft. Finally, the nylon balloon with ePTFE covering on which the VBX Stent Graft is loaded promotes stent retention. When considering the complexity of the disease being managed today by endovascular means, I believe that limiting potential device related issues is conceivably very impactful.

The ICARUS trial evaluated three-year

safety and effectiveness outcomes associated with the iCast covered stent. At three years, Laird *et al* demonstrated a late clinical success rate of 72.4% and a freedom from TLR rate of 86.6%. It is though critical to emphasise that although the results are very similar to the values achieved in the VBX FLEX study, the two trials are not exactly comparable when it comes to patient selection. Indeed, only 5.8% of lesions treated in the ICARUS trial were TASC C and there were no TASC D lesions treated in the trial. Similarly, the BOLSTER trial, which evaluated the Lifestream® balloon expandable vascular covered stent, only had 9.7% (n = 15) TASC C and 1.3% (n = 2) TASC D lesions included in the trial. The VBX FLEX study was formulated to reflect current practice patterns, which promotes an endovascular first approach for all lesions including TASC C and D lesions. Therefore, 32% of the lesions treated in the VBX FLEX study were TASC C or D.

Additionally, in the VBX FLEX study, 42.5% of stents were placed in a kissing stent configuration, which usually has an inferior long-term patency. Despite this, the clinically-driven TLR at nine months and three years was 98.6% and 98.1%, respectively, while the freedom from clinically-driven TVR was 98.1% and 97.1% at nine months and three years, respectively.

In conclusion, it would seem that despite all three trials achieving respectable results, in light of the increased severity of the lesions in the VBX FLEX study, it is safe to say that the VBX Stent Graft is an efficacious tool in the management of aorto-iliac occlusive disease. The combination of improved procedural safety with features such as trackability and stent retention, with the ability to maintain good long-term outcomes in real-world aorto-iliac disease provides a unique advantage for the VBX Stent Graft.

*Jean Bismuth is a specialist vascular surgeon at Houston Methodist Hospital (Houston, USA).*

References for this article can be found online at [www.vascularnews.com](http://www.vascularnews.com).

# Case report: “A global solution for treatment of complex disease”

**Manuel Alonso, Lino Cambor and Amer Zanabli**, vascular surgeons at the Hospital Universitario Central de Asturias (HUCA), Oviedo, Spain, explain how to use a combination of self-expanding and balloon expandable covered stents to obtain durable results.

## Case report

A 69-year-old man with a past medical history of arterial hypertension, chronic obstructive pulmonary disease and prior smoking presented with severe left lower limb claudication. On physical examination, the left femoral pulse was absent. Ankle-brachial index demonstrated a value of 0.98 on the right side and 0.58 on the left. The patient was initially treated with an exercise walking programme and optimal medical therapy for six months; however, he continued suffering from a severe lifestyle-limiting claudication. A CT scan on the abdomen and both lower limbs was performed in order to get a precise evaluation of the arterial lesions, demonstrating a severely calcified occlusion of the left common iliac artery (5.7 cm in length) with a minimal proximal stump, diffuse stenosis of the whole external iliac artery and severely diseased hypogastric artery on the left side. A significant stenosis, higher than 50%, was noticed in the homolateral common femoral artery. On the right iliac axis, a moderate stenosis with slight calcification was noticed at the origin of the common iliac artery. There were no significant lesions at the level of infrarenal aorta and both infrainguinal sectors. Given these findings, a decision was taken to proceed with a hybrid intervention. Under spinal anaesthesia, an open exposure of the left common femoral artery and its branches was performed. A short 6 Fr introducer sheath was placed and a first ipsilateral attempt to cross the common iliac occlusion was performed without success either using an intraluminal or subintimal recanalisation technique. An 8 Fr introducer sheath was placed in the right common femoral artery under ultrasound guidance; however, after several attempts, the antegrade recanalisation was also impossible using the crossover technique, probably due to the severe calcification of the occlusion.

Finally, the recanalisation of the left iliac axis was achieved from a homolateral groin approach using the **CORDIS® OUTBACK® ELITE Re-entry Catheter** and an **ABBOTT COMMAND ES Guidewire 0.014”**. After

that, a **BOSTON SCIENTIFIC AMPLATZ SUPER STIFF** Guidewire was placed in the upper abdominal aorta through both iliac axes from each groin. During the next step of the procedure, a left common femoral artery endarterectomy plus synthetic patch angioplasty was performed. An 8 Fr and 35 cm length sheath was placed through the patch, and two 8 L x 79 mm **GORE® VIABAHN® VBX Balloon Expandable Endoprostheses (VBX Stent Grafts)** were implanted using the kissing stent technique, following with an 8 x 150 mm self-expanding **GORE® VIABAHN® Endoprostheses** covering all the length of the left external iliac artery which was post-dilated with an 8 x 150 mm PTA balloon. Therefore, flaring of the aortic segment of both VBX Stent Grafts was performed using two 12 x 40 mm PTA balloons to get an appropriate apposition of both VBX Stent Grafts to the aortic wall.

Final angiography revealed excellent stent expansion with no residual stenosis. A percutaneous closure device (**ABBOTT® PROGLIDE® Suture-Mediated Closure System**) was employed for haemostasis on the right side, and conventional closure was performed on the left groin. The patient was discharged home on the third postoperative day on a daily regimen including aspirin 100 mg, clopidogrel 75 mg and atorvastatin 20 mg daily. At six-month follow-up, duplex ultrasound showed patency of both iliac axes and the patient did not complain of any claudication.

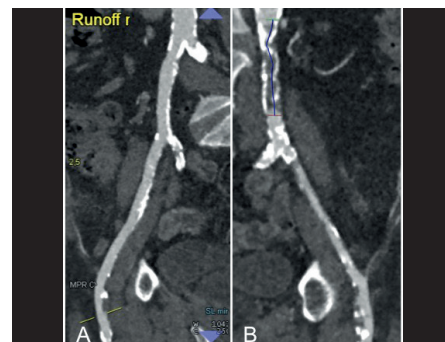
## What are your indications for either endovascular or open treatment?

Based in the latest good, long-term results with the use of covered stents,<sup>1</sup> the algorithm at our department for treating patients with critical limb ischaemia or invalidating claudication and aortoiliac lesions, is an endovascular-first strategy, whenever it does not compromise any subsequent open surgical option. We still perform open surgery in young fit patients with juxtarenal aortic occlusion. Like other authors,<sup>2</sup> we have found worse results, both by endovascular and open

surgery approaches, in women, mainly if they have small arteries (< 6 mm); for that reason, we avoid treating them for claudication.

## When do you perform a femoral endarterectomy or patch angioplasty in conjunction with endovascular treatment?

In those cases where aorto-iliac lesions also involve the common femoral artery, we perform a hybrid procedure with an open CFA endarterectomy and profundoplasty if it is needed. We perform this technique in around 75% of all our cases with complex aorto-iliac occlusive disease.<sup>3</sup> There are two objectives of this additional technique: one being to create a healthy landing zone for the covered stent graft and the second is to guarantee an appropriate outflow through the common femoral artery. If the common femoral artery diameter was < 6 mm and healthy we would perform a patch angioplasty without endarterectomy to avoid oversizing at the distal end of the covered stent.




**Figure 1: CT-angiography reconstructions.** A. Right iliac axis with a mild stenosis at the origin of the common iliac artery. B. Left iliac axis with a severely calcified occlusion of the left common iliac artery with a minimal proximal stump, diffuse stenosis of the whole external iliac artery and common femoral artery significant stenosis.


## Is there any role for external iliac artery endarterectomy during an endovascular or hybrid repair?

Although aortoiliac recanalisation has a high technical success rate, we have to be very cautious with the presence of severely calcified lesions, as it is one of the best markers for failure of an arterial recanalisation. When the severe calcification affects the common iliac artery, we recommend being prepared with a possible brachial access and also a re-entry device should be available, just in case. If the heavy calcification involves the external iliac artery, we try to perform





Manuel Alonso



Antonio Camblor



Amer Zanabilli

a retrograde endarterectomy with an over-the-wire AESCULAP® VOLLMAR Dissector to facilitate the correct expansion of the self-expanding GORE® VIABAHN® Endoprosthesis.

**Is it better to get an adequate distal landing zone above or distally to the inguinal ligament?**

The distal external iliac artery is under a high mechanical stress, especially when it crosses the hip joint. For that reason, the choice of the most adequate stent is a crucial issue. We always use the self-expanding GORE® VIABAHN® Endoprosthesis due to its high conformability that avoids kinking or stent

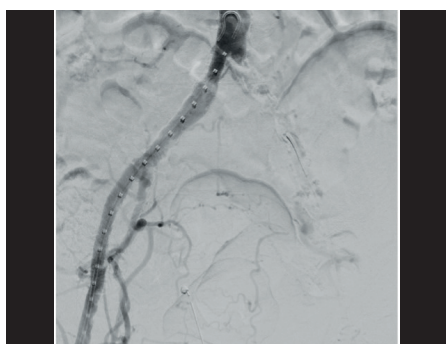
**technique?**

If the aorto-iliac disease is located at the distal aorta, involving proximal common iliac arteries bilaterally or if there is not a proximal healthy stump; both, classical kissing-stenting or the CERAB technique can be performed. The CERAB configuration showed in experimental studies superior flow geometry and more physiological flow patterns; however, self-expanding covered stents were not tested. In any case, it has achieved good results in the mid-term with primary and secondary patency rates at three years of 82% and 97%, respectively, and a multicentre registry is underway. However, it has got three theoretical drawbacks: more collateral pathways need to be sacrificed with uncertain consequences (inferior mesenteric artery, lumbar arteries, accessory renal arteries); in up to 45 – 50% of cases it is necessary to

**Why do you prefer both covered stents from Gore instead of other covered stents?**

The self-expanding GORE® VIABAHN® Endoprosthesis has demonstrated to be a very reliable device for treatment of different types of pathologies for more than 20 years. We prefer it over other available options for the treatment of this sector due to several reasons: its excellent flexibility and adaptability to tortuous anatomy, it is the only one with a heparin bioactive surface protecting against thrombus formation and it has the most extensive range of lengths, up to 25 cm.

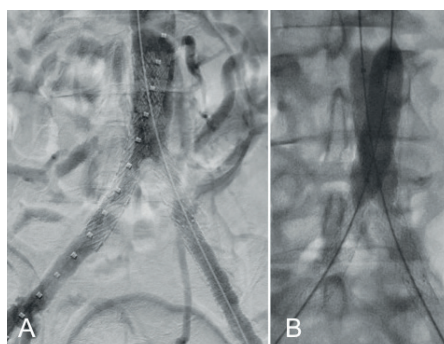
We really also believe that the new VBX Stent Graft brings some advantages that other balloon expandable covered stents do not provide. It is the longest balloon expandable covered stent in the market, up to 79 mm. It could be useful in long common iliac arteries and in some cases of kissing stent technique. When they are used in the kissing stent configuration, we can also flare the aortic segment to get an appropriate apposition to the aortic wall.



**Figure 2: Intraoperative angiography:** Occlusion of the left common iliac artery. Notice that the vertebral catheter is occluding the lumen of the left external iliac artery. Moderate stenosis at the origin of the right common iliac artery.

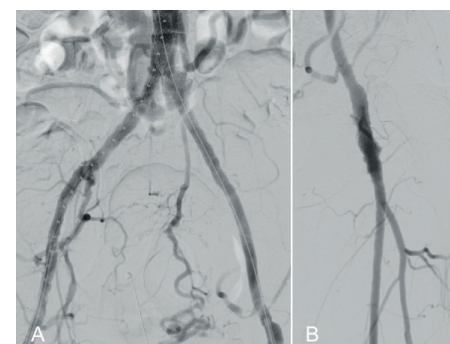
fracture in the distal external iliac artery, especially when it crosses the inguinal ligament. Whenever possible, we prefer to deploy the distal edge of the self-expanding GORE® VIABAHN® Endoprosthesis 1 or 2 cm above the circumflex arteries to avoid the most stressful forces represented by the inguinal ligament. If we cannot do it, we prefer to cross the inguinal ligament in order to get a “healthy” landing zone in the common femoral artery. So far, we have not detected a self-expanding GORE® VIABAHN® Endoprosthesis fracture. In fact, the stent-graft obtained a primary patency rate higher than 90% at midterm follow-up.

**When do you perform kissing stenting and when a CERAB**



**Figure 3: Intra-procedural angiographic details.** A. Angiography after kissing stenting with 2 GORE® VIABAHN® VBX Balloon Expandable Endoprosthesis 8L x 79 mm. B. Flaring of the aortic segment of both VBX Stent Grafts with 2 PTA balloons 12 x 40 mm.

use four or five stents; and it could be less practical when the aortic diameter is larger than 16 mm. For those reasons, in most of our cases we prefer to use the covered kissing-stent technique in a particular manner to achieve a “D-shape configuration”. We perform this configuration using VBX Stent Graft to create a “neo aorto-iliac bifurcation” and flaring both VBX Stent Graft aortic segments, at a level where there is no aortic thrombus, with two 12 – 16 x 20 – 40 mm non-compliant angioplasty balloons. With this configuration we avoid the dead space between the stent grafts at the native aorta, optimising the flow pattern. If a long segment of the infrarenal aorta is diseased, then the CERAB technique is our preferred choice.



**Figure 4: Final angiography.** A. Patency of the aortoiliac sector without significant stenosis. Notice that the inferior mesenteric artery remains patent B. Patency of the common, superficial and deep femoral arteries.

In summary, with both the self-expanding GORE® VIABAHN® Endoprosthesis and the GORE® VIABAHN® VBX Balloon Expandable Endoprosthesis, Gore offers a global approach for treatment of complex aorto-iliac occlusive disease.

**References**

- Mwipatayi BP, Sharma S, Daneshmand A, et al. Durability of the balloon-expandable covered versus bare-metal stents in the Covered versus balloon expandable stent trial (COBEST) for the treatment of aortoiliac occlusive disease. *J Vasc Surg.* 2016;64:83–94.
- Piazza M, Squizzato F, Bassini S, et al. The impact of female sex on the outcomes of endovascular treatment for iliac lesions. *J Vasc Surg.* 2019 Nov 11. pii: S0741-5214(19)32358-4. doi: 10.1016/j.jvs.2019.08.271. [Epub ahead of print]
- Zanabilli Al-Sibbai AA, Camblor Santervás LA, Álvarez Marcos F, et al. Midterm results of endovascular treatment for complete iliac axis occlusions using covered stents. *Ann Vasc Surg.* 2020;63:241–9.

# Challenging procedure with the GORE® VIABAHN® VBX Balloon Expandable Endoprosthesis

Alexander Massmann describes a challenging bilateral iliac case treated with the GORE® VIABAHN® VBX Balloon Expandable Endoprosthesis (VBX Stent Graft).

A 72 - YEAR - OLD MALE PRESENTED with lifestyle-compromising impaired walking distance < 100 m. Comorbidities include chronic heart disease and COPD caused by active smoking. Imaging using contrast-enhanced magnetic resonance imaging angiography and computed tomography angiography depicted a stenosing chronic ulceration and dissection of the infrarenal aorta (Figure 1a – c).

Presence of mixed thrombus and calcification caused bilateral aortoiliac high-grade stenosis. In addition, there were large-calibre bilateral accessory renal arteries and the inferior mesenteric artery originating from the distal infrarenal aorta (Figure 2).

After interdisciplinary consensus of the vascular board and informed consent, the patient favoured an endovascular treatment approach using an anatomic hybrid reconstruction of the aortoiliac bifurcation referring to the CERAB technique.<sup>1</sup>

For preservation of the relevant renal and descending colon / sigmoid vascular supply, a large diameter bare-metal self-expanding nitinol OPTIMED SINUS-XL Stent 18 / 62 mm) was placed into the infrarenal aorta via a transfemoral 10 Fr sheath. Accurate deployment cranial to the aortic bifurcation and caudal to the main renal arteries was achieved by contralateral transfemoral access

and an angiographic run using a diagnostic pigtail catheter. Using a bare-metal stent in the infrarenal aorta allowed for preservation of the significant visceral supply to the renals and the descending colon / sigmoid, preventing impairment of renal function or colorectal ischaemia. Owing to the large cell dimensions, there is no relevant coverage of the ostia of the visceral arteries.

After withdrawal of the stent delivery catheter, catheterisation of the true stent

**“The presented hybrid technique using bare metal and covered stent grafts resulted in successful anatomic reconstruction of complex aorto-iliac bifurcation stenosis.”**

lumen was performed and verified from the contralateral transfemoral access.

For fixation of bilateral aorto-iliac mixed



Alexander Massmann

thrombus and calcification two covered stent grafts (VBX Stent Graft 10 / 59 mm) were used in kissing-stent configuration. The 59 mm VBX Stent Graft (final length after balloon inflation 55.3 mm) was chosen to avoid impairment

of the inferior mesenteric and internal iliac arteries' offspring. The cross-sectional area of the large-diameter BMS is about 255 mm<sup>2</sup>. The cross-sectional area of both 10 mm stent grafts results in 157 mm<sup>2</sup> to allow for flow optimisation.<sup>2</sup> Aorto-iliac adequate stent and stent graft alignment was performed using 12 mm kissing balloons resulting in a cross-sectional area of 226 mm<sup>2</sup>.<sup>2</sup>

The presented hybrid technique using bare-metal and covered stent grafts resulted in successful anatomic reconstruction of complex aorto-iliac bifurcation stenosis with respect to cost-effectiveness of aorto-iliac stent grafting, while preserving significant visceral artery perfusion (Figure 3).<sup>3</sup>

*Alexander Massmann is an interventional radiologist at the Saarland University Medical Center in Homburg/Saar, Germany.*

## References

1. Goverde PC, Grimme FA, Verbruggen PJ, Reijnen MM. Covered endovascular reconstruction of aortic bifurcation (CERAB) technique: A new approach in treating extensive aortoiliac occlusive disease. *J Cardiovasc Surg (Torino)*. 2013 Jun;54(3):383–7.
2. Groot Jebbink E, Mathai V, et al. Haemodynamic comparison of stent configurations used for aortoiliac occlusive disease. *J Vasc Surg*. 2017 Jul;66(1):251–260.e1. doi: 10.1016/j.jvs.2016.07.128.
3. Taeymans K, Groot Jebbink E, et al. Three-year outcome of the covered endovascular reconstruction of the aortic bifurcation technique for aortoiliac occlusive disease. *J Vasc Surg*. 2018 May;67(5):1438–1447. doi: 10.1016/j.jvs.2017.09.015.

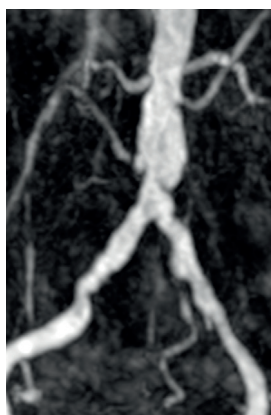

Figure 1a

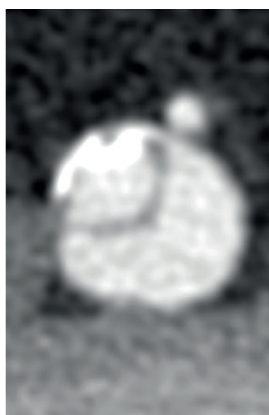


Figure 1b

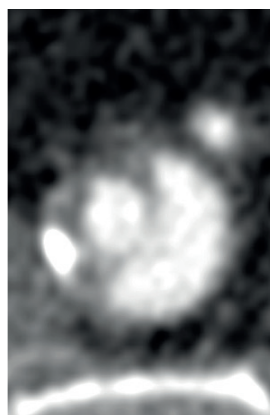


Figure 1c

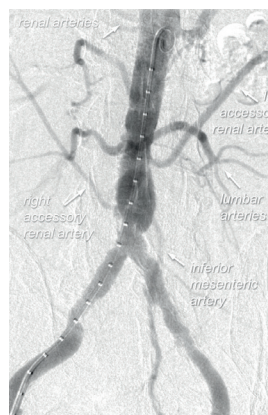


Figure 2

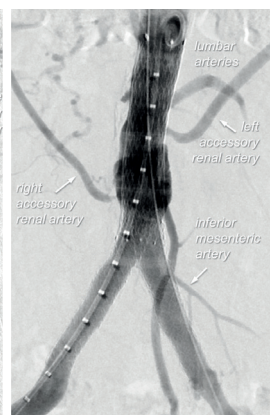

Figure 3



# “Good for complex anatomy”: Use of the GORE® VIABAHN® VBX Balloon Expandable Endoprosthesis in a CERAB case

**Rutger Lely** discusses his clinical experience using the GORE® VIABAHN® VBX Balloon Expandable Endoprosthesis (VBX Stent Graft) in CERAB (covered endovascular reconstruction of the aortic bifurcation) cases, detailing why it is particularly well-suited to this procedure.



Rutger Lely

## CERAB case study

For a CERAB case, we begin by discussing the patient in an MDT or multidisciplinary team, which always includes a vascular surgeon and an interventional radiologist. We then consider potential treatment options, like open surgery or endovascular treatment and discuss the CT scan. For this type of case I would then use the large, 11 mm VBX Stent Graft. This is a covered stent that goes through an 8 Fr sheath. This is very important because the smaller the better when it comes to endovascular treatment. We use a long guiding sheath to pass the occlusion or the stenosis and then we place the main body.

## When should you consider the CERAB procedure?

The normal indication for a CERAB procedure could be a claudicant patient, due to an occlusion — or near occlusion — of the aorto-iliac arteries. Two months ago, I treated a patient who was bleeding from a pseudoaneurysm of the common iliac artery and it had started to bleed in his ureter. When he came into the emergency room (ER), his blood pressure was 50 over 40 mmHg and his heart rate was over 100 bpm. We transported him to the vascular suite and performed a CERAB. All went well and the most recent CT (February 2020) shows elimination of the pseudoaneurysm and the uteroiliac fistula. Of course, we are excited to see what the CT results will be at six months and one year, but, at the moment, he is doing well. That is a nice indication to perform a CERAB because it is rare, whereas you see a lot of literature for stenosis, stenotic lesions and aneurysms.

## What are the benefits of this approach?

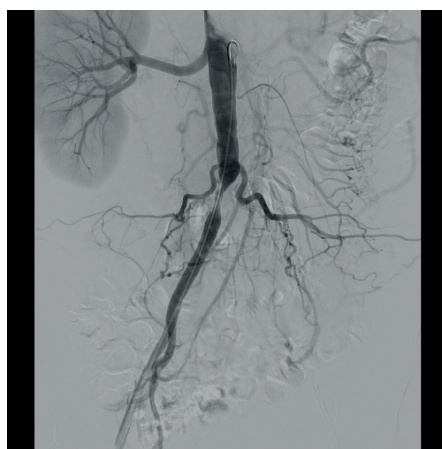There are a number of benefits to performing a CERAB because you do a big procedure through only two tiny holes in the groins and you can do it under local anaesthesia. This is a big advantage. I had one patient — a young man — who I treated under local anaesthesia and was able to go home the same day.

## How and when would you use the VBX Stent Graft specifically in this case?

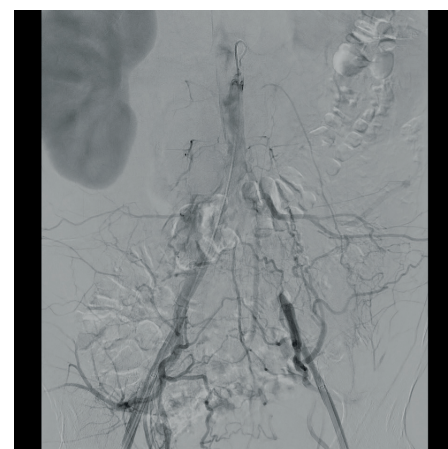
There are some key benefits of using the VBX Stent Graft in a CERAB case. One is that you go through a smaller diameter, which

that because the VBX Stent Graft has a lower profile, it is more suited to tortuosity. The VBX Stent Graft can deal with curves in the vasculature; this is a very important feature in our job. It is good for complex anatomy and small vessels. I had one renal artery aneurysm case where I had to take a couple of turns and the VBX Stent Graft acted very well. Finally, the VBX Stent Graft is available in the length of 79 mm, which other vendors do not offer.

*Rutger Lely is an interventional radiologist at the Amsterdam University Medical Center (Amsterdam, the Netherlands).*



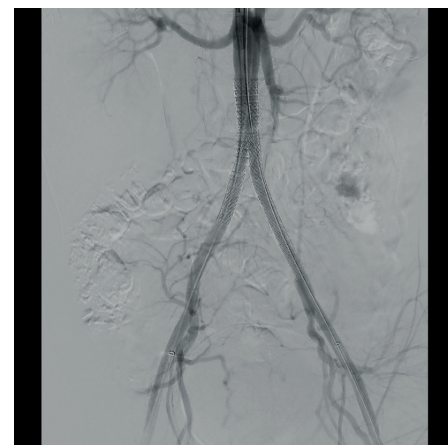Pre-CERAB angiogram



Pre-CERAB angiogram

“The VBX Stent Graft stays better on the balloon and can deal with curves. Both of these things are really important.”

is the main reason I always recommend that stent. The second is that the VBX Stent Graft stays better on the balloon — that is a big advantage in my view. Another advantage is



Post-CERAB angiogram



# GORE® VIABAHN® VBX Balloon Expandable Endoprosthesis



## Flexible Strength. Proven Success.

- 100% restoration of lumen diameter<sup>1</sup>
- 100% maintenance of stent length<sup>1</sup>
- 100% stent delivery at target site with no stent dislodgement<sup>1</sup>
- 96.9% primary patency at 9 months<sup>1</sup>

See flexible strength in action:

[goremedical.com/eu/vbx-expands](https://goremedical.com/eu/vbx-expands)



1. Bismuth J, Gray BH, Holden A, Metzger C, Panneton J; VBX FLEX Study Investigators. Pivotal study of a next-generation balloon-expandable stent-graft for treatment of iliac occlusive disease. *Journal of Endovascular Therapy* 2017;24(5):629-637.