

# Endovascular TODAY

June 2015



**COMPLETE COVERAGE FOR  
COMPLEX IN-STENT  
RESTENOSIS**

Data, comparative analysis, and consensus  
on the role of the GORE® VIABAHN® Endoprosthesis.

# Complete Coverage for Complex In-Stent Restenosis

Despite the increased sophistication of peripheral endovascular interventions, in-stent restenosis (ISR) remains a prevalent problem. A historical deficiency in data on the best treatment options further complicates the ability to use an algorithmic approach to this challenging presentation. As study results begin to reveal the much-needed data interventionists have eagerly anticipated to aid treatment decisions, we inch closer in coming to a consensus on the best way to approach these lesions.

In March 2015, Gore & Associates gathered 17 thought leaders in the interventional cardiology community to discuss their protocols for optimal ISR treatment. We

highlight the presentations and case reports from the meeting in the following articles. Additionally, throughout the forum, the physician audience was polled with a number of questions on their practice preferences, a few of which are featured in this supplement in the “Ask the Experts” segments to illustrate the personal protocols of this esteemed group. We thank this group for their time and meaningful contributions to the information that appears here.

We hope you will find this supplement to *Endovascular Today* a comprehensive look at the available data and analysis on ISR.

## CONTENTS

- 3 Data-Driven Treatment Approach to In-Stent Restenosis**  
*By George L. Adams, MD, MHS, FACC, FSCAI; Robert M. Bersin, MD, FACC, FSCAI; Jon C. George, MD, FACC, FSCAI; Vinayak Subramanian, BS; Peter A. Soukas, MD, FACC, FSVM, FSCAI, FACP, RPVI*
- 9 Case Report: The GORE® VIABAHN® Endoprosthesis for In-Stent Restenosis in the Superficial Femoral Artery**  
*By Robert L. Minor, Jr, MD, and Jeffrey R. Cook, MD*
- 11 Case Report: The GORE® VIABAHN® Endoprosthesis for Recurrent In-Stent Restenosis**  
*By Peter A. Soukas, MD, FACC, FSVM, FSCAI, FACP, RPVI*
- 13 Case Report: Treating ISR With the GORE® VIABAHN® Endoprosthesis After Bilateral SFA CTO Interventions**  
*By Robert M. Bersin, MD, FACC, FSCAI*
- 15 Innovation Fueling Evolution: Two Decades of the GORE® VIABAHN® Endoprosthesis**  
*By M. Casey Becker, MD, FACC, FSCAI, FSVM*
- 17 Optimal Technique for Use of the GORE® VIABAHN® Endoprosthesis**  
*By Barry S. Weinstock, MD, FACC*

Gore products referenced within are used within their FDA approved/cleared indications. Gore does not have knowledge of the indications and FDA approval/clearance status of non-Gore products. Gore makes no representations as to the surgical techniques, medical conditions or other factors that may be described in this supplement. The reader is advised to contact the manufacturer for current and accurate information.

# Data-Driven Treatment Approach to In-Stent Restenosis

BY GEORGE L. ADAMS, MD, MHS, FACC, FSCAI; ROBERT M. BERSIN, MD, FACC, FSCAI; JON C. GEORGE, MD, FACC, FSCAI; VINAYAK SUBRAMANIAN, BS; PETER A. SOUKAS, MD, FACC, FSVM, FSCAI, FACP, RPVI

More than 81 million Americans are affected by some form of cardiovascular disease.<sup>1,2</sup> Peripheral artery disease (PAD) is a growing public health concern in the United States and affects 8 million Americans.<sup>2,3</sup> Left untreated, PAD can result in increasingly morbid outcomes.<sup>4</sup> Endovascular revascularization of occluded arteries is the ideal course of treatment. Placement of stents is the standard course of treatment for occluded coronary arteries; however, stent placement presents unique challenges when used in the peripheral arteries due to the dynamic stresses and motion of the arteries. Furthermore, in-stent restenosis (ISR) due to neointimal hyperplasia after stent implantation has plagued the field and has emerged as the Achilles' heel of this era of vascular interventions.

Although there have been promising developments in treating ISR, data supporting these novel therapies have lagged behind. This article details the results from three randomized trials comparing different therapies to standard percutaneous transluminal angioplasty (PTA) for ISR: the FAIR trial, which looked at drug-coated balloons (DCBs); the EXCITE ISR trial, which studied excimer laser atherectomy (ELA); and the RELINE trial, which analyzed the use of the GORE® VIABAHN® Endoprosthesis.

## PATHOPHYSIOLOGY

ISR can be defined either clinically or angiographically. Clinically, it is defined as hemodynamically significant stenosis within a stent causing recurrent ischemia. Angiographically, it is defined as the presence of > 50% diameter stenosis within a stent.<sup>5</sup>

The artery can be divided into three distinct layers: the intima consisting of endothelial cells, the media made up of smooth muscle cells, and the adventitia made up of collagen fibers and fibroblasts. Balloon angioplasty and stenting of an artery induces a localized inflammatory response, which precipitates neointimal proliferation and tissue growth.<sup>6,7</sup> Peripheral arteries undulate and are subjected to the triplanar intermittent stresses of compression, flexion, and torsion. The placement of a stent inhibits the artery's natural movement. Furthermore, current nitinol stent systems are oversized for use in peripheral arteries and result in chronic outward radial force that causes long-term inflammation. Thus, the placement of the stent results in mechanical trauma to the walls of the artery, which in turn triggers an inflam-

matory response. The basement membrane of the media is fractured, resulting in a phenotypic switch of the smooth muscle cells from quiescent to proliferative. The mechanical trauma results in inflammation in the adventitia, which acts as positive feedback for the phenotypic switch of the smooth muscle cells of the media and also results in further proliferation of fibrotic cells. The proliferation and fibrosis in these two layers ultimately manifests in the migration of this overgrowth into the media, resulting in neointimal hyperplasia.<sup>8,9</sup>

Cellular proliferation can potentially result in significant ISR, thereby causing recurrence or deterioration of clinical symptoms, necessitating target lesion revascularization (TLR). Several anatomic and clinical risk factors increase the overall occurrence of restenosis, including longer lesion lengths, smaller vessel diameters, and diabetes mellitus.<sup>10</sup>

## INCIDENCE OF IN-STENT RESTENOSIS

Stent placement in peripheral arteries is associated with a high rate of ISR; it has been reported to occur in up to 40% of femoropopliteal lesions treated with bare-metal stents within 1 year of treatment.<sup>11-13</sup> The most common course of treatment after ISR is PTA; however, nearly 65% of patients will return with ISR following this retreatment within 2 years. Recently, the VIASTAR trial showed a 1-year ISR rate of 45% and a 2-year rate of 58.8% in bare-metal stents and 36.9% at 2 years with the GORE VIABAHN Device.<sup>14</sup>

## CLASSIFICATION

A classification scheme for management of ISR lesions was recently proposed by Tosaka et al.<sup>15</sup> The lesions are classified by visual estimate on angiography (Figure 1):

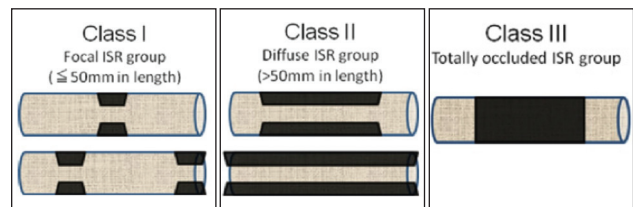


Figure 1. Visual estimate of lesion classification on angiography. Reprinted from *J Am Coll Cardiol*, Vol 59, Tosaka A, Soga Y, Iida O, et al, Classification and clinical impact of restenosis after femoropopliteal stenting, pg 16-23, Copyright 2012, with permission from Elsevier.<sup>15</sup>

- Class I: the focal (≤ 50 mm in length) ISR group; includes lesions within the stent body, edge, or a combination.
- Class II: the diffuse (> 50 mm in length) ISR group; includes stent body and edge lesions.
- Class III: the totally occluded ISR group; includes chronic occlusion within the entire length of the stent.

A classification system, such as the Tosaka classification, allows for targeted optimal therapy based on the disease state. Similar to the TASC classification system<sup>16</sup> for de novo PAD, the Tosaka classification could dictate the best evidence-based treatment strategies for each tier of the classification system.

**DATA LANDSCAPE**

Treatment options for ISR include PTA, cutting or scoring balloons, atherectomy devices, covered stent systems, DCBs, drug-eluting stents, and/or direct drug delivery. In an initial study conducted by Dick et al comparing the rates of binary ISR after using either conventional PTA or cutting-balloon angioplasty, it was found that both treatments were ineffective and were associated with a 6-month restenosis rate of 73%.<sup>17</sup> Most reports of ISR treatment have been single-center, observational studies with limited follow-up. However, there have been three recent multicenter, prospective, randomized trials comparing therapeutic options for the treatment of ISR: the EXCITE ISR trial, the FAIR trial, and the RELINE trial.

**EXCITE ISR Trial**

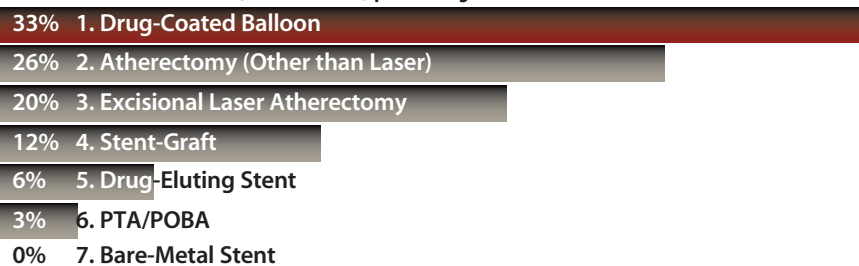The EXCITE ISR trial was a multicenter, randomized study that aimed to compare the efficacy of ELA and PTA versus conventional PTA alone in treating femoro-popliteal ISR. The study was the

**ASK THE EXPERTS**

**Expert panel indicated that the GORE VIABAHN Device is the therapy they are most likely to use in long, Tosaka Class II lesions and Tosaka Class III ISR occlusions.**


**4-cm Tosaka Class I Lesion**

In order of primacy, which three therapies are you most likely to use as your primary treatment for a 4-cm stenosed ISR lesion (Tosaka Class I) presenting for the first time as an ISR lesion?



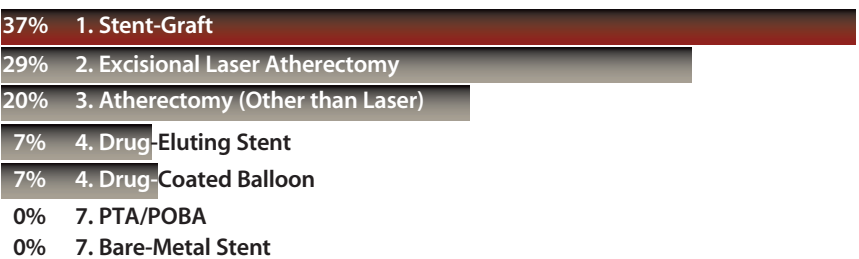
**10-cm Tosaka Class II Lesion**

In order of primacy, which three therapies are you most likely to use as your primary treatment for a diffusely stenosed 10-cm ISR lesion (Tosaka Class II) that required one intervention 14 months ago?



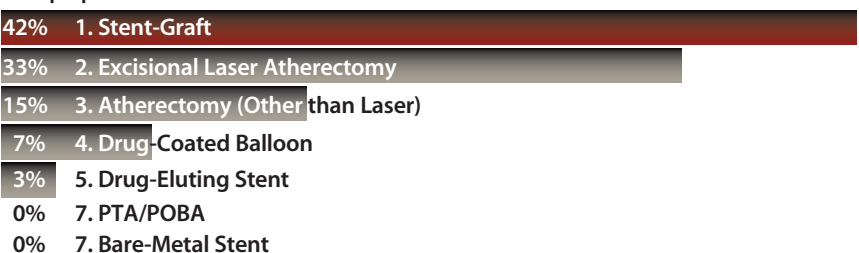
**17-cm Tosaka Class II Lesion**

In order of primacy, which three therapies are you most likely to use as your primary treatment for a diffusely stenosed 17-cm ISR lesion (Tosaka Class II) that required three interventions in the past 18 months?



**20-cm+ Tosaka Class III Lesion**

In order of primacy, which three therapies are you most likely to use as your primary treatment for a chronically occluded stent with a stenosed length of 20+ cm (Tosaka Class III) that required multiple prior reinterventions?



first randomized trial to demonstrate the benefits of utilizing atherectomy in combination with PTA in the lower extremities.<sup>18</sup> There were 250 patients randomized 2:1 between 2011 and 2014 at 40 sites. The primary efficacy endpoint of the study was determined by freedom from clinically driven TLR at 6 months. This included binary restenosis (unspecified peak systolic velocity ratio), return of clinical symptoms, and deteriorated ankle-brachial index or Rutherford classification.

The study included real-world, long ISR lesions averaging 19.6 cm in the ELA+PTA arm and 19.3 cm in the PTA-alone arm. The use of ELA resulted in a significantly higher procedural success rate of 93.5% compared with 82.7% for PTA alone ( $P = 0.03$ ). The use of ELA was also associated with a significantly higher rate of freedom from major adverse events compared with PTA alone (94.2% vs 79.2%, respectively; intent-to-treat,  $P < 0.001$ ). Lastly, the ELA+PTA arm demonstrated both a significantly higher patency rate (approximately 40% for ELA+PTA vs 20% for PTA) at 12 months and a higher rate of freedom from TLR after 12 months (approximately 47% for ELA+PTA vs 28% for PTA).

**FAIR Trial**

The FAIR trial was a randomized, controlled trial aimed at assessing the efficacy of DCB angioplasty to standard PTA in treating ISR of the superficial femoral artery. There were 119 patients randomized 1:1 at five sites. The primary endpoint of the trial was the 6-month binary restenosis rate (> 50%) as evidenced by duplex ultrasound with a peak systolic velocity ratio > 2.4. The secondary endpoints included technical success of access and treatment resulting in < 50% residual stenosis. Additionally, the study aimed to measure 12-month recurrent ISR of > 50% and freedom from TLR at 6 months and 12 months. Overall, the FAIR trial looked at shorter lesions, averaging approximately 8.2 cm in length in both study arms. At 12 months, there was a significant improvement in primary patency in the DCB group (DCB, 70.5% vs standard PTA, 38.5%;  $P = 0.004$ ). Freedom from clinically driven TLR also increased in the DCB group (DCB, 90.8% vs standard PTA, 52.6%;  $P < 0.0001$ ).<sup>19,20</sup>

**THE GORE VIABAHN DEVICE FOR IN-STENT RESTENOSIS**

The GORE VIABAHN Device has been applied in the treatment of ISR lesions for many years, and in theory, this ePTFE-lined endoprosthesis may be a more attractive alternative by virtue of the fact that recurrence risk is independent of lesion length.<sup>14</sup> The SALVAGE trial, a prospective, single-arm trial of ELA followed by implantation of a GORE VIABAHN Device in ISR lesions, supported the safety of this approach with a decreased need for repeat revascularization (17.4% at 12 months).<sup>21</sup> Kazemi et al reported a 65% 12-month primary patency rate for 17 patients with ISR and an average lesion length of 15 cm.<sup>22</sup> Ansel et al noted a 65% 12-month primary patency rate for 27 patients with an average lesion length of

26 cm.<sup>23</sup> Monahan et al reported a 62% 12-month primary patency rate in 24 patients,<sup>24</sup> and Gorgani et al reported a 63% primary patency rate at 24 months for 22 patients with an average lesion length of 21.4 cm.<sup>25</sup> Al-Shammeri et al noted 83% 12-month and 81% 36-month primary patency rates for 27 patients with an average lesion length of 24.4 cm.<sup>26</sup> Of note, 35.7% of patients in this series were treated with adjunctive ELA before stent graft implantation, 25% of patients received concomitant inflow interventions, and 39% were treated with outflow interventions.

Prompted in part by these very encouraging findings of the application of the GORE VIABAHN Device in ISR lesions, a prospective, multicenter, randomized trial of PTA versus the GORE VIABAHN Device for the treatment of femoropopliteal ISR lesions (RELIN trial) was conducted.

**RELIN Trial Design**

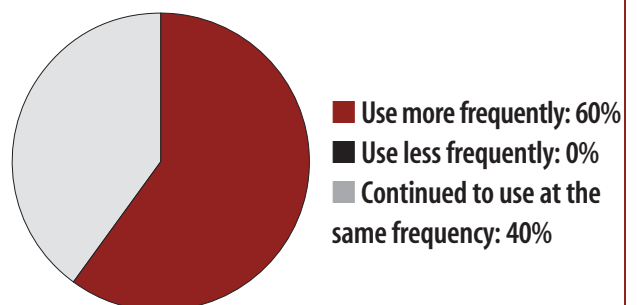
The RELIN clinical study was a prospective, randomized trial conducted at seven centers in Europe comparing the GORE VIABAHN Device versus PTA for the treatment of ISR of the superficial femoral artery.<sup>27</sup> This study was designed as a real-world trial that sought to enroll a wide range of patients (Rutherford category 2–5) with ISR of the superficial femoral artery with a wide range of lesion lengths (4–27 cm) and with a minimum of one vessel runoff that did not require intervention. Key exclusion criteria were untreated, flow-limiting inflow stenoses; aneurysms of the superficial femoral artery; no intact runoff vessel; and a documented history of type 2 heparin-induced thrombocytopenia.<sup>27</sup>

**RELIN Trial Enrollment**

This trial prospectively randomized 100 patients to PTA treatment or GORE VIABAHN Device implantation 1:1. Fifty-three patients were randomized to PTA, and 47 patients were randomized to the GORE VIABAHN Device. Nine patients in the PTA arm and eight patients in the GORE VIABAHN Device arm were excluded due to inclusion/exclusion and/or procedural violations. This left 44 patients in the PTA arm

**ASK THE EXPERTS**

**How will the data from the RELIN trial impact your use of the GORE VIABAHN Device for ISR?**



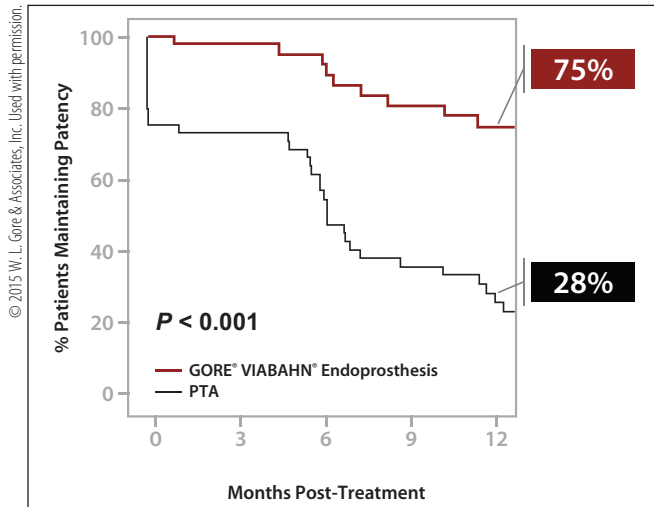


Figure 2. Twelve-month primary patency rates for the GORE VIABAHN Device compared to PTA in the per-protocol analysis.

TABLE 1. 12-MONTH PRIMARY PATENCY			
	GORE VIABAHN Device	PTA	P Value
Intent-to-treat	72.5%	24.2%	< 0.001
Per-protocol	75%	28%	< 0.001
Optimal PTA (as treated)	75%	37%	< 0.001

TABLE 2. FREEDOM FROM TLR AT 12-MONTH FOLLOW-UP			
	GORE VIABAHN Device	PTA	P Value
Intent-to-treat	81%	41%	< 0.001
Per-protocol	80%	42%	< 0.001
Optimal PTA (as treated)	80%	54%	< 0.001

and 39 patients in the GORE VIABAHN Device arm available for per-protocol analysis. The vast majority of patients enrolled were Rutherford category 2 or 3 (only 21% in the PTA arm and 13% in the GORE VIABAHN Device arm were Rutherford category 4 or 5). Approximately one-third of the patients in both treatment groups were diabetic, and approximately 40% were current smokers in both groups.

**RELINE Trial Results**

The mean lesion length was 19 cm (range, 3–27 cm) in the PTA arm and 17.3 cm (range, 3–33 cm) in the GORE VIABAHN Device arm. There were nine bailout stent procedures after failed PTA in the PTA arm and none in the GORE VIABAHN Device arm. The as-treated (“optimal PTA”) analysis excluded the nine patients who underwent bailout stenting.

At 12 months, the primary patency rate was 28% in the PTA arm and 75% in the GORE VIABAHN Device arm (Figure 2 and Table 1).

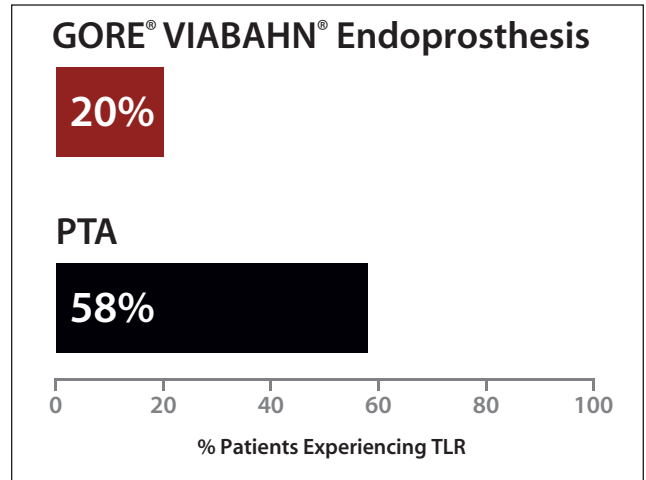
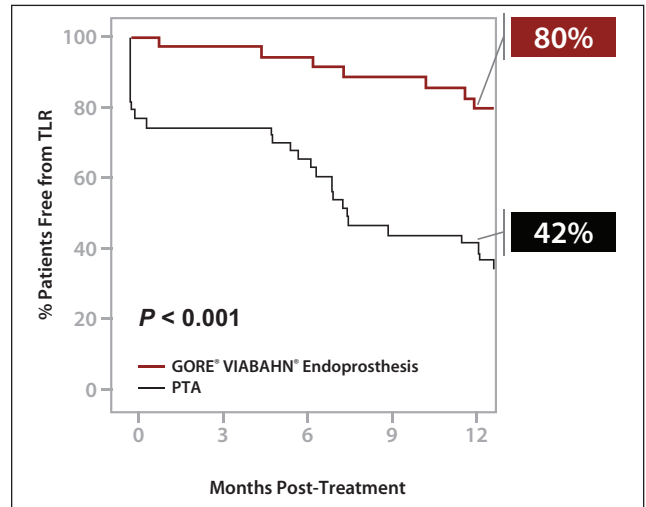


Figure 3. At 12 months, TLR rates were almost three times higher for patients who received PTA versus those who were treated with the GORE VIABAHN Device (Kaplan-Meier estimates of freedom from TLR in the per-protocol analysis).

The 12-month primary patency according to intent-to-treat, per-protocol, and optimal PTA analyses all demonstrated a highly statistically significant difference between the two arms of the study (Table 1). The percentage of patients requiring TLR up to 12 months was three times lower for the GORE VIABAHN Device arm (Figure 3 and Table 2).

Device-related adverse events were infrequent in both treatment arms at 5.8% in the PTA arm and 2.2% in the GORE VIABAHN Device arm ( $P = 0.62$ ). Zero GORE VIABAHN Device fractures were identified by the core angiographic laboratory. At 12 months, clinical success was maintained (at least one Rutherford category improvement in claudication symptoms) in 85% of patients in the PTA arm and 94% of patients in the GORE VIABAHN Device arm ( $P = 0.139$ ).

**RELINE Trial Conclusions**

This prospective, randomized trial demonstrated superiority of the GORE VIABAHN Device as compared with PTA in

the treatment of restenotic nitinol stents in the superficial femoral artery, with superior primary patency at 12 months, and an approximately threefold reduction in the number of patients requiring a TLR rate at 12 months. This trial also demonstrated a low incidence of serious device-related adverse events in both arms of the study and an absence of fracture of the GORE VIABAHN Device in this application.

**RANDOMIZED TRIALS IN PERSPECTIVE**

The RELINE clinical study demonstrated superiority of the GORE VIABAHN Device as compared with PTA in the treatment of femoropopliteal ISR lesions. The only other prospective, multicenter, randomized trials evaluating other treatments compared with PTA were the EXCITE-ISR trial of ELA and the FAIR trial of paclitaxel DCBs.<sup>18,20</sup>

Although comparisons of these trials are complicated by the fact that the patient populations and average lesion lengths varied, it appears the application of the GORE VIABAHN Device is associated with a very favorable 12-month primary patency rate and freedom from need of repeat intervention (Table 3).

Tosaka et al established that lesion length and/or the presence of a stent occlusion are predictors of patency and the need for subsequent reintervention in ISR lesions undergoing PTA.<sup>14</sup>

ELA enhances the outcomes after treatment of ISR lesions with DCBs.<sup>28</sup> Whether ELA (or other forms of atherectomy) also enhances the performance of the GORE VIABAHN Device in ISR lesions is not established, as the SALVAGE trial was a single-arm trial.

**RANDOMIZED TRIAL SUMMARY**

ISR continues to be a prevalent problem in the field of peripheral endovascular interventions. As the impact of PAD on health care resources increases in the United States, the need for devices that can answer the problem of restenosis is critical. The

**TABLE 3. RECENT RANDOMIZED, PROSPECTIVE, MULTICENTER ISR TRIALS**

	FAIR Trial		EXCITE ISR Trial		RELINE Trial	
	IN.PACT Drug-Coated Balloon (Medtronic)	PTA	ELA + PTA (Spectranetics Corporation)	PTA	GORE VIABAHN Device	PTA
Mean lesion length (cm)	8.2	8.2	19.6	19.3	17.3	19
% CTOs	24%	33%	31%	37%	23%	25%
Moderate to severe calcification	10%*	9%*	27%	9%	33%	25%
Primary patency at 12 months	70.5%	37.5%	40%**	20%**	75%	28%
Freedom from TLR at 12 months	91%	53%	47%**	28%**	80%	42%

\*RELINE trial and EXCITE ISR trial report "moderate to severe calcification," while the FAIR trial reports only "heavy calcium."  
 \*\*1-year estimates based on Kaplan-Meier curves.<sup>17</sup>

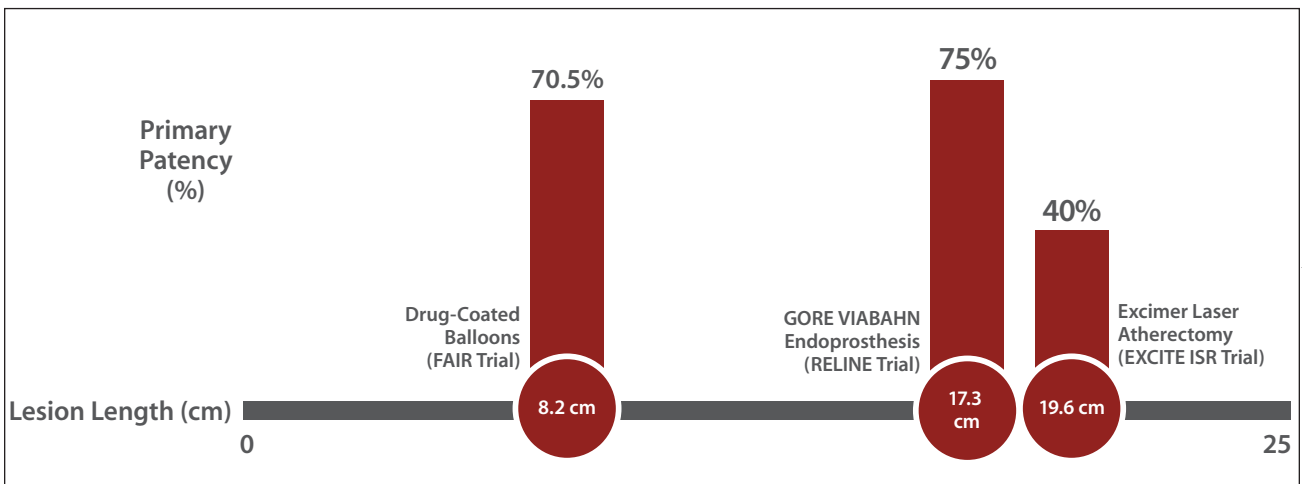


Figure 4. Twelve-month primary patency for ISR by lesion length.<sup>18,20,27</sup> The EXCITE-ISR trial and RELINE trial evaluated longer lesion lengths (over 17 cm) compared with the short mean lesion length of 8.2 cm in the FAIR trial.

© 2015 W. L. Gore & Associates, Inc. Used with permission.

**In summary, the limited number of multicenter, prospective, randomized ISR trials highlight the remarkable performance of the GORE VIABAHN Device in a patient population where other therapies either are not studied or underperform.**

data landscape of randomized, controlled trials is scant. The FAIR trial, EXCITE ISR trial, and RELINE trial have demonstrated the benefit of new and innovative strategies to tackle this clinical challenge.

Both the EXCITE-ISR trial and the RELINE trial studied similar “real-world” long lesion lengths of over 17 cm as compared with the short mean lesion length of 8.2 cm in the FAIR trial (Figure 4). Despite being studied in lesions over twice as long as in the FAIR trial, the primary patency at 12 months was numerically greater for the GORE VIABAHN Device in the RELINE trial. In contrast to the relatively poor performance of ELA in long ISR lesions, the GORE VIABAHN Device demonstrated exceptional patency in these lesions.

In summary, the limited number of multicenter, prospective, randomized ISR trials highlight the remarkable performance of the GORE VIABAHN Device in a patient population where other therapies either are not studied or underperform. ■

*George L. Adams, MD, MHS, FACC, FSCAI, is with Rex Hospital, University of North Carolina Health System in Raleigh, North Carolina. He has disclosed that he is a consultant for Gore & Associates, Medtronic, and Spectranetics.*

*Robert M. Bersin, MD, FSCAI, FACC, is Medical Director of Endovascular Services and Medical Director of Structural Heart Services at Swedish Medical Center in Seattle, Washington. He has disclosed that he is a consultant to Medtronic, Spectranetics Corporation, and Gore & Associates. Dr. Bersin may be reached at robert.bersin@swedish.org.*

*Jon C. George, MD, FACC, FSCAI, is with the Division of Interventional Cardiology and Endovascular Medicine, Deborah Heart and Lung Center in Browns Mills, New Jersey. He has disclosed that he is a consultant for Abbott Vascular, Boston Scientific Corporation, Cook Medical, Gore & Associates, Medtronic, and Spectranetics Corporation. Dr. George may be reached at jcgeorgemd@hotmail.com.*

*Vinayak Subramanian, BS, is with the Department of Biomedical Engineering, North Carolina State University in Raleigh, North Carolina. He has stated that he has no financial interests related to this article.*

*Peter A. Soukas, MD, FACC, FSVM, FSCAI, FACP, RPVI, is Director of Vascular Medicine and the Interventional PV*

*Laboratory, Director of the Brown Vascular & Endovascular Medicine Fellowship at The Miriam and Rhode Island Hospitals, and Assistant Professor of Medicine at the Warren Alpert School of Medicine of Brown University in Providence, Rhode Island. He has disclosed that he is an unpaid consultant to Gore & Associates, Cordis Corporation, Bard Peripheral Vascular, Spectranetics Corporation, and Medtronic; and receives trial research grant support from Gore & Associates, Cordis Corporation, Bard Peripheral Vascular, Spectranetics Corporation, Mercator, Abbott Vascular, Medtronic, and Biotronik. Dr. Soukas may be reached at psoukas@lifespan.org.*

1. Fleg JL, Forman DE, Berra K; American Heart Association Committees on Older Populations and Exercise Cardiac Rehabilitation and Prevention of the Council on Clinical Cardiology, Council on Cardiovascular Nursing, and Council on Lifestyle and Cardiometabolic Health. Secondary prevention of atherosclerotic cardiovascular disease in older adults: a scientific statement from the American Heart Association. *Circulation*. 2013;128:2422-2246.
2. Roger VL, Go AS, Lloyd-Jones DM, et al. Heart disease and stroke statistics—2012 update: a report from the American Heart Association. *Circulation*. 2012;125:e2-e220.
3. Ouriel K. Peripheral arterial disease. *Lancet*. 2001;358:1257-1264.
4. Varu VN, Hogg ME, Kibbe MR. Critical limb ischemia. *J Vasc Surg*. 2010;51:230-241.
5. Teirstein PS, Massullo V, Jani S, et al. Catheter-based radiotherapy to inhibit restenosis after coronary stenting. *N Engl J Med*. 1997;336:1697-1703.
6. Singh S, Armstrong E, Laird J. Understanding iliac and femoropopliteal artery restenosis. *Endovascular Today*. 2013;8:36-40.
7. Hoffmann R, Mintz GS, Dussault GR, et al. Patterns and mechanisms of in-stent restenosis. A serial intravascular ultrasound study. *Circulation*. 1996;94:1247-1254.
8. Kornowski R, Hong MK, Tio FO, et al. In-stent restenosis: contributions of inflammatory responses and arterial injury to neointimal hyperplasia. *J Am Coll Cardiol*. 1998;31:224-230.
9. Kearney M, Pieczek A, Haley L, et al. Histopathology of in-stent restenosis in patients with peripheral artery disease. *Circulation*. 1997;95:1998-2002.
10. Mehran R, Dangas G, Abizaid AS, et al. Angiographic patterns of in-stent restenosis: classification and implications for long-term outcome. *Circulation*. 1999;100:1872-1878.
11. Bosiers M, Torsello G, Gissler HM, et al. Nitinol stent implantation in long superficial femoral artery lesions: 12-month results of the DURABILITY I study. *J Endovasc Ther*. 2009;16:261-269.
12. Krankenberg H, Schluter M, Steinkamp HJ, et al. Nitinol stent implantation versus percutaneous transluminal angioplasty in superficial femoral artery lesions up to 10 cm in length: the femoral artery stenting trial (FAST). *Circulation*. 2007;116:285-292.
13. Scheiner D, Katsanos K, Zeller T, et al. A prospective randomized multicenter comparison of balloon angioplasty and infrapopliteal stenting with the sirolimus-eluting stent in patients with ischemic peripheral arterial disease: 1-year results from the ACHILLES trial. *J Am Coll Cardiol*. 2012;60:2290-2295.
14. Lammer J, Zeller T, Hausegger KA, et al. Sustained benefit at 2 years for covered stents versus bare-metal stents in long SFA lesions: the VIASTAR trial. *Cardiovasc Intervent Radiol*. 2015;38:25-32.
15. Tosaka A, Soga Y, Iida O, et al. Classification and clinical impact of restenosis after femoropopliteal stenting. *J Am Coll Cardiol*. 2012;59:16-23.
16. Norgren L, Hiatt WR, Dormandy JA, et al. Inter-society consensus for the management of peripheral arterial disease (TASC II). *J Vasc Surg*. 2007;45:55-67.
17. Dick P, Sabeti S, Mlekusch W, et al. Conventional balloon angioplasty versus peripheral cutting balloon angioplasty for treatment of femoropopliteal artery in-stent restenosis: initial experience. *Radiology*. 2008;248:297-302.
18. Dippel EJ, Makam K, Kovach R, et al. Randomized controlled study of excimer laser atherectomy for treatment of femoropopliteal in-stent restenosis: initial results from the EXCITE ISR trial (EXCimer Laser Randomized Controlled Study for Treatment of Femoropopliteal In-Stent Restenosis). *J Am Coll Cardiol Interv*. 2015; 8:92-101.
19. Ju MH, Rodriguez HE. Standard balloon angioplasty versus angioplasty with paclitaxel-eluting balloons for femoropopliteal artery stenosis. *J Cardiovasc Surg (Torino)*. 2012;53:459-463.
20. Krankenberg H. FAIR: drug-eluting balloon versus PTA for superficial femoral artery in-stent restenosis: 12 month results. Presented at: LINC 2014; January 28-31, 2014; Leipzig, Germany.
21. Laird JR Jr, Yeo KK, Rocha-Singh K, et al. Excimer laser with adjunctive balloon angioplasty and heparin-coated self-expanding stent grafts for the treatment of femoropopliteal artery in-stent restenosis: twelve-month results from the SALVAGE study. *Catheter Cardiovasc Interv*. 2012;80:852-859.
22. Kazemi S, Djelalmi-Hani M, Gupta A, et al. One year patency rate of the VIABAHN stent-graft for chronic total occlusion or long high-grade stenosis of the superficial femoral artery. Abstract presented at the 18th Annual Scientific Symposium of the Transcatheter Cardiovascular Therapeutics (TCT); October 22-27, 2006; Washington, DC. *American Journal of Cardiology*. 2006;98(8)Supplement S1:235M-236M. TCT-607.
23. Ansel GM, Boti CF II, Taylor M, Silver MJ. A 2007 update on treating nitinol stent restenosis. *Endovascular Today*. 2007;6:80-82.
24. Monahan TS, Vartanian S, Schneider DB. Effective treatment of femoropopliteal in-stent restenosis with stent grafts. *J Vasc Surg*. 2011;33:917-918.
25. Gorgani F, Telis A, Narakathu N, et al. Long-term outcomes of the Viabahn stent in the treatment of in-stent restenosis in the superficial femoral artery. *J Invasive Cardiol*. 2013;25:670-674.
26. Al Shammeri O, Bitar F, Ghilelman J, Soukas PA. Viabahn for femoropopliteal in-stent restenosis. *Ann Saudi Med*. 2012;32:575-582.
27. Bosiers B, Deloose K, Callaert J, et al. Superiority of stent-grafts for in-stent restenosis in the superficial femoral artery: twelve-month results from a multicenter randomized trial. *J Endovasc Ther*. 2015;22:1-10.
28. Gandini R, Del Giudice C, Merolla S, et al. Treatment of chronic SFA in-stent occlusion with combined laser atherectomy and drug-eluting balloon angioplasty in patients with critical limb ischemia: a single-center, prospective, randomized study. *J Endovasc Ther*. 2013 Dec;20:805-814.



# The GORE® VIABAHN® Endoprosthesis for In-Stent Restenosis in the Superficial Femoral Artery

BY ROBERT L. MINOR, JR, MD, AND JEFFREY R. COOK, MD

A 59-year-old African American woman was initially evaluated for limiting right calf claudication. Lower extremity Doppler exam revealed a resting ABI of 0.75 in the right leg. Her past medical history was notable for diabetes, hypertension, hyperlipidemia, and prior cigarette smoking. Medications included metformin, lisinopril, lovastatin, and aspirin. Initial peripheral angiography demonstrated a chronic total occlusion (CTO) spanning 10 cm of the middle segment of the right superficial femoral artery (SFA) (Figure 1A). Interventions at that time involved implantation of three bare-nitinol SFA stents measuring 5.5 X 100 mm, 5.5 X 60 mm, and 6 X 60 mm in the distal, mid, and proximal SFA, respectively (Figure 1B). The patient was initiated on clopidogrel. However, 6 months after her index procedure, she developed severe recurrent symptoms. Repeat right lower extremity Doppler exam revealed a resting ABI of 0.54,

and an exercise ABI of 0.28. Repeat angiography demonstrated severe and diffuse in-stent restenosis throughout the entire stented segment of the right SFA (Figure 2A). Regarding the run-off vessels, there was a distal occlusion of the posterior tibial artery, but patent anterior tibial and peroneal arteries (Figure 2B).

## PROCEDURAL DESCRIPTION

The patient underwent repeat endovascular intervention using the left common femoral approach. A 7-F sheath (Cook Medical) was advanced in a contralateral fashion to the right common femoral artery. A steerable 0.035-inch Versacore guidewire (Abbott Vascular) was used to traverse the right SFA. A Quick-Cross catheter (Spectranetics Corporation) was advanced over this wire into the right popliteal artery, and the wire was exchanged for a 5-mm-diameter SpiderFX distal embolic protection filter (Medtronic). The entire segment of the right SFA with in-stent restenosis was then treated using rotational

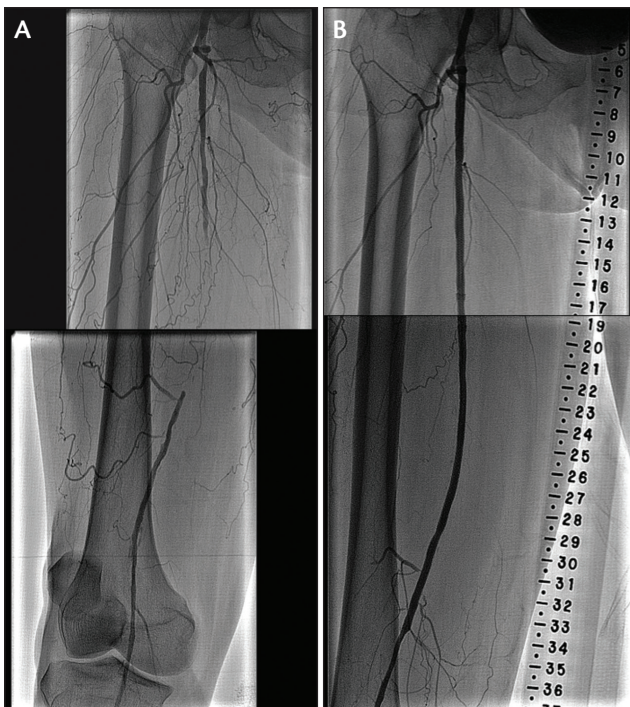


Figure 1. CTO in the right SFA (A). Initial procedural completion angiogram after treatment with bare-nitinol stents (B).

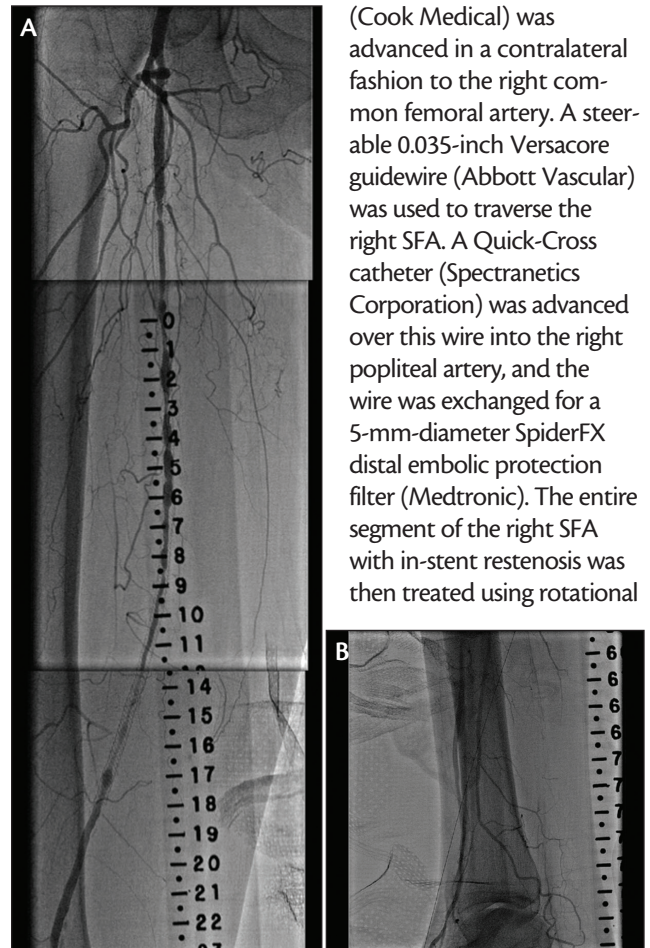


Figure 2. Diffuse in-stent restenosis of the SFA 6 months after implantation (A). Two-vessel tibial runoff (B).

CASE REPORT

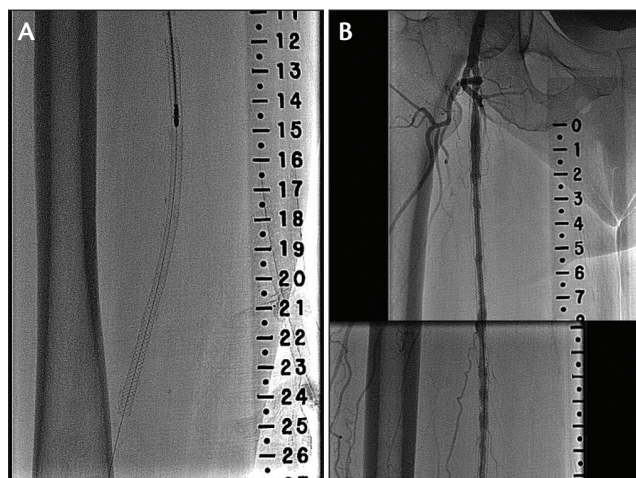


Figure 3. Rotational atherectomy device with distal embolic protection filter (A). Angiogram after rotational atherectomy (B).

atherectomy (Figures 3A and 3B). Balloon angioplasty was then performed using a Fox sv 5- X 100-mm angioplasty balloon (Abbott Vascular). Subsequently, a 5- X 250-mm GORE VIABAHN Device with Heparin Bioactive Surface was implanted in the distal and midsegment of the region of in-stent restenosis in the right SFA, followed by a second 6- X 50-mm GORE VIABAHN Device in the proximal segment. Postdilatation was performed with the FOX sv 5- X 100-mm balloon in the distal and mid-segments, followed with a FOX sv 6- X 100-mm balloon in the proximal segment, maintaining balloon inflations within the edges of the GORE VIABAHN Devices. Nevertheless, a distal edge dissection was discovered, and a third 5- X 50-mm GORE VIABAHN Device was placed. The embolic protection filter was retrieved and inspected, revealing successful capture of tissue consistent with intimal hyperplasia.

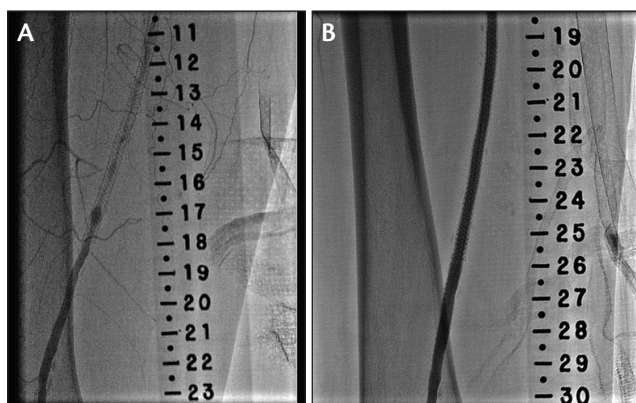


Figure 5. Magnified image of severe in-stent restenosis of the stent in the distal SFA (A). Magnified image after treatment with the GORE VIABAHN Device (B).

**The use of the GORE VIABAHN Device with Heparin Bioactive Surface provides an excellent treatment option for in-stent restenosis in the SFA, particularly when it involves a long stented segment.**

RESULTS

Completion angiography revealed a widely patent right SFA with brisk flow and no residual stenosis (Figure 4). There was also excellent distal flow into the pedal arch vasculature, with no evidence of distal tissue embolization. The patient was continued on clopidogrel and low-dose aspirin. She has remained asymptomatic, and follow-up Doppler exam performed 9 months after placement of the GORE VIABAHN Devices for in-stent restenosis confirmed improvement in the right leg resting ABI from 0.54 to 1.0.

DISCUSSION

The use of the GORE VIABAHN Device with Heparin Bioactive Surface provides an excellent treatment option for in-stent restenosis in the SFA, particularly when it involves a long stented segment. In this case, rotational atherectomy with embolic filter protection was used to initially debulk the restenotic tissue. With the subsequent use of both balloon pre- and postdilatation, placement of GORE VIABAHN Devices resulted in an angiographic result suggesting optimal expansion throughout the SFA containing the previously implanted stents (Figures 5A and 5B). ■

*Robert L. Minor, Jr, MD, is an interventional cardiologist with the OSF Saint Anthony Medical Center in Rockford, Illinois. He has disclosed that he is a consultant for Gore & Associates and Medtronic.*

*Jeffrey R. Cook, MD, is an interventional cardiologist with the OSF Saint Anthony Medical Center in Rockford, Illinois. He has stated that he has no financial interests related to this article.*

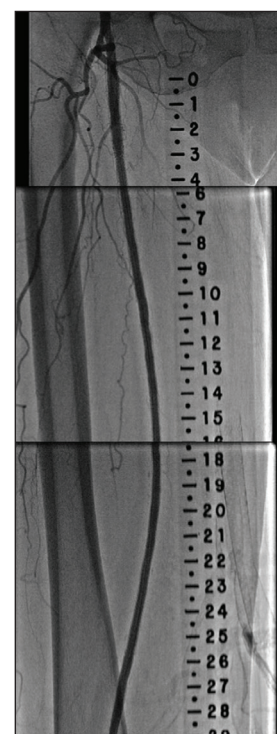


Figure 4. Completion angiogram after placement of the GORE VIABAHN Device for in-stent restenosis in the SFA.

# The GORE® VIABAHN® Endoprosthesis for Recurrent In-Stent Restenosis

BY PETER A. SOUKAS, MD, FACC, FSVM, FSCAI, FACP, RPVI

A 62-year-old man was transferred to our hospital from one of our sister institutions with unstable angina and a positive troponin test. He was a former smoker with a history of hypertension, hyperlipidemia, and coronary artery disease, and had undergone percutaneous coronary intervention with a drug-eluting stent for an 80% stenosis of the mid-left circumflex artery.

He was referred for cardiac rehabilitation 1 month after the intervention, but was unable to adequately exercise due to disabling claudication. Upon assessment in the cath lab, he was found to have a high-grade superficial femoral artery (SFA) lesion (Figure 1).

The patient was still working and active, so he refused surgery and was referred for peripheral vascular intervention in September 2004. He underwent standard balloon angioplasty and was treated with overlapping self-expanding nitinol stents with a good acute angiographic result (Figure 2).

## PROCEDURAL DESCRIPTION

Unfortunately, the patient required four reinterventions over the following 2 years due to recurrent in-stent restenosis. First, in May 2005 he underwent cutting balloon angioplasty and cryoplasty. Seven months later, in December 2005, he returned and underwent repeat cutting-balloon angioplasty and cryoplasty. Another 7 months later, in June 2006, we performed laser atherectomy and cryoplasty, but the restenosis returned.

Finally, in November 2006 (Figure 3), he was treated with a cutting balloon and three 6-mm-diameter GORE VIABAHN Devices (Figure 4). Completion angiography showed a patent SFA with < 10% residual stenosis (Figure 5). He was treated with 81 mg aspirin and 75 mg clopidogrel daily.

## RESULTS

The patient has remained asymptomatic with normal resting bilateral ankle-brachial indexes of 1.0, triphasic

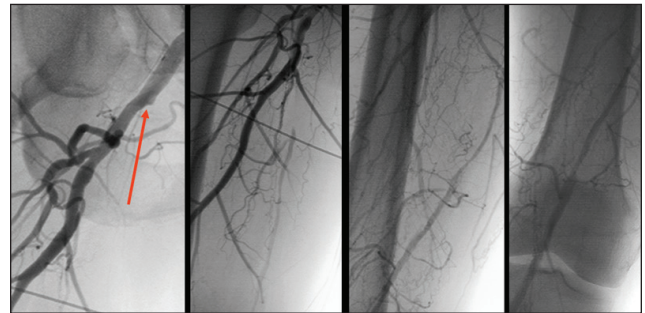


Figure 1. Baseline angiograms showing a high-grade lesion. The SFA origin (arrow) is shown in the left panel.

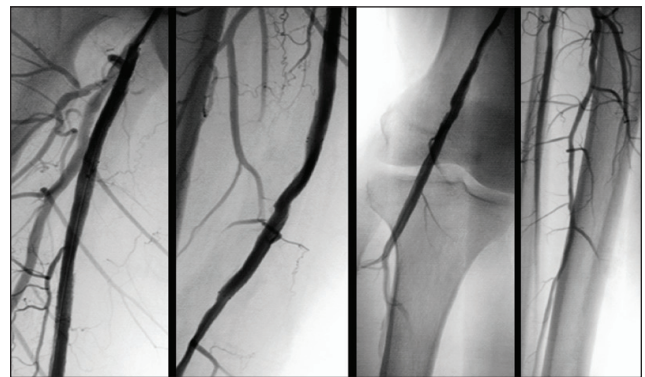


Figure 2. Final angiograms after the patient underwent PTA and received bare-metal stents.

waveforms on duplex ultrasound, and no claudication since the index procedure. I saw this patient again in May 2015 and the GORE VIABAHN Devices are still patent, even more than 8 years after they were implanted.

## DISCUSSION

The last several years have seen a burgeoning number of randomized trials proving the superiority of endolumi-

### SEPTEMBER 2004:

Referred for peripheral vascular intervention. Underwent standard balloon angioplasty and received nitinol stents.

### MAY 2005:

Underwent cutting balloon angioplasty and cryoplasty.

### DECEMBER 2005:

Underwent repeat cutting balloon angioplasty and cryoplasty.

### JUNE 2006:

Underwent laser atherectomy and cryoplasty.

### NOVEMBER 2006:

Underwent cutting balloon angioplasty and received three GORE VIABAHN Devices.

### MAY 2015:

Patient remains asymptomatic with no claudication.

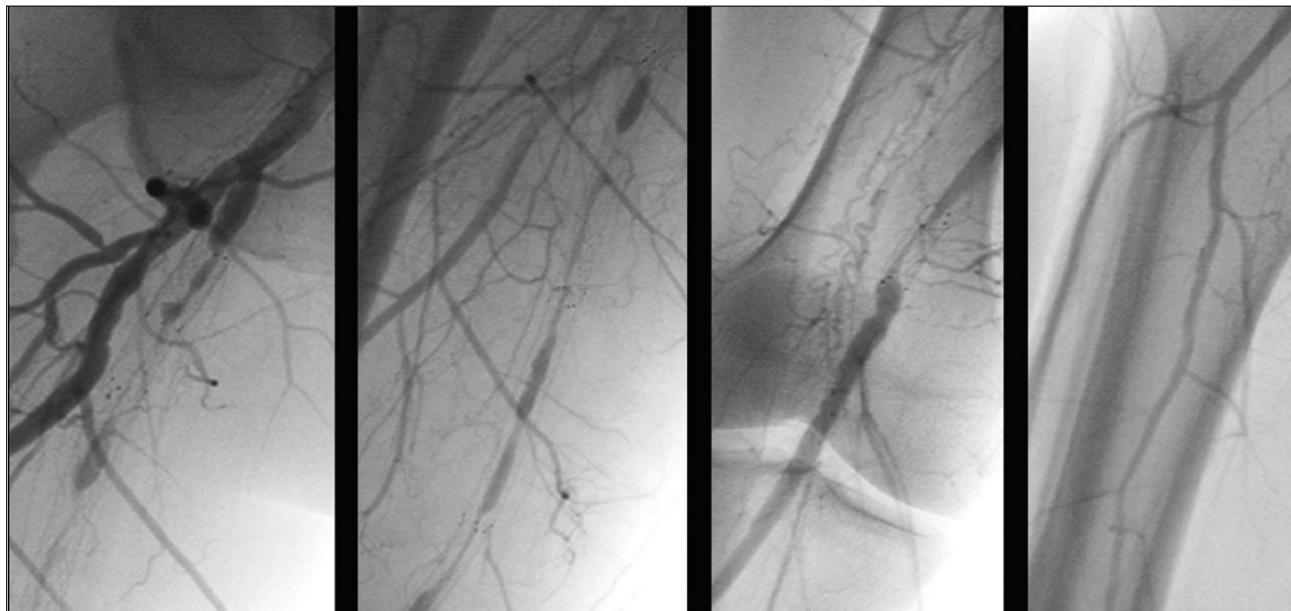


Figure 3. Baseline angiograms in November 2006 before treatment with covered stents.

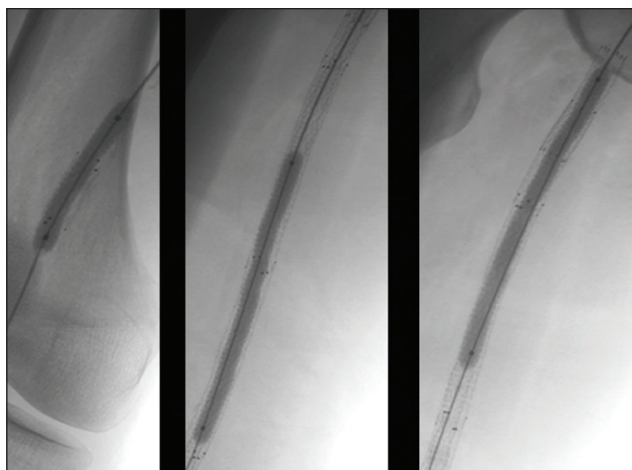


Figure 4. The patient underwent PTA with cutting balloons and stent-grafting with GORE VIABAHN Devices.

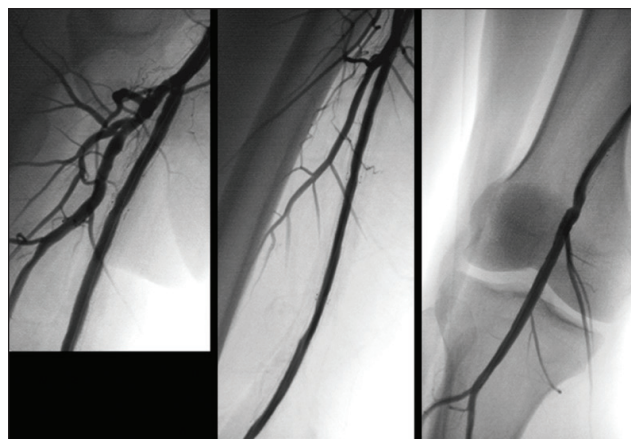


Figure 5. Completion angiograms showing a patent SFA.

**“ We have witnessed superior outcomes with the GORE VIABAHN Device for treatment of in-stent restenosis, as illustrated by the greater than 8-year patency observed in this case. ”**

nal stenting over balloon angioplasty. Although stenting overcomes the immediate limitations of arterial dissection and elastic recoil, it comes at the price of potential in-stent restenosis. We have witnessed superior outcomes with the GORE VIABAHN Device for treatment of in-stent restenosis, as illustrated by the greater than 8-year patency observed in this case. ■

*Peter A. Soukas, MD, FACC, FSVM, FSCAI, FACP, RPVI, is Director of Vascular Medicine and the Interventional PV Laboratory, Director of the Brown Vascular & Endovascular Medicine Fellowship at The Miriam and Rhode Island Hospitals, and Assistant Professor of Medicine at the Warren Alpert School of Medicine of Brown University in Providence, Rhode Island. He has disclosed that he is an unpaid consultant to Gore & Associates, Cordis Corporation, Bard Peripheral Vascular, Spectranetics Corporation, and Medtronic; and receives trial research grant support from Gore & Associates, Cordis Corporation, Bard Peripheral Vascular, Spectranetics Corporation, Mercator, Abbott Vascular, Medtronic, and Biotronik. Dr. Soukas may be reached at [psoukas@lifespan.org](mailto:psoukas@lifespan.org).*

# Treating ISR With the GORE® VIABAHN® Endoprosthesis After Bilateral SFA CTO Interventions

BY ROBERT M. BERSIN, MD, FACC, FSCAI

**Based on the RELINE trial data and my clinical experience, the GORE VIABAHN Device is an excellent choice for treating long-segment de novo as well as in-stent restenotic occlusions.**

**A** 64-year-old man presented with Rutherford category 3 bilateral lower extremity claudication symptoms. The patient's past medical history included hypertension, diabetes mellitus, hypercholesterolemia, and mild carotid artery disease.

Lower extremity angiography in August 2012 showed bilateral mild to moderate disease in the common iliac arteries, bilateral occlusions of the internal iliac arteries, and bilateral chronic total occlusions (CTOs) of the superficial femoral artery (SFA) at the ostium, reconstituting above the knee distally via profunda collaterals.

In October 2012, the patient underwent a right SFA CTO recanalization using the Crosser catheter (Bard Peripheral Vascular) and the Pioneer Plus reentry catheter (Volcano Corporation) with placement of three GORE VIABAHN Devices (two 6-mm stent-grafts and one 7-mm) and a 7- X 60-mm self-expanding stent in the right external iliac artery.

A month later, the left SFA and above-knee popliteal CTO were recanalized using the Pioneer Plus reentry catheter, directional atherectomy, and placement of three 6-mm self-expanding stents.

The patient returned in June 2014 with recurrent lower left extremity symptoms. His ankle-brachial index was 0.91 on the right side and 0.48 on the left. Vascular ultrasound showed reocclusion of the left SFA. Angiography confirmed reocclusion

of the left SFA stents, but the GORE VIABAHN Devices in the right SFA remained widely patent (Figure 1). The runoff remained normal in both lower extremities (Figure 2).

## PROCEDURAL DESCRIPTION

The patient then underwent a repeat endovascular intervention to the left SFA, initially a 2.3-mm laser atherectomy (Figure 3A), followed by AngioJet™ Solent thrombectomy (Boston Scientific Corporation) (Figure 3B), followed by EkoSonic® lysis (Ekos Corporation, a BTG International

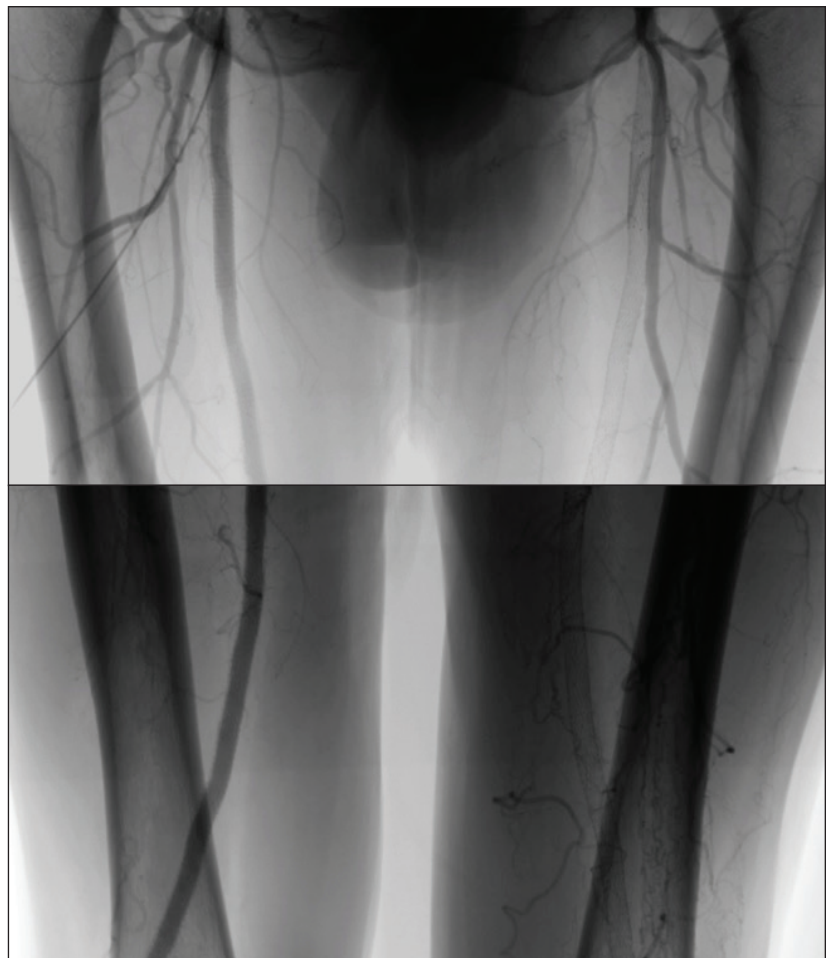

Figure 1. Angiograms of the left SFA showed in-stent occlusion.

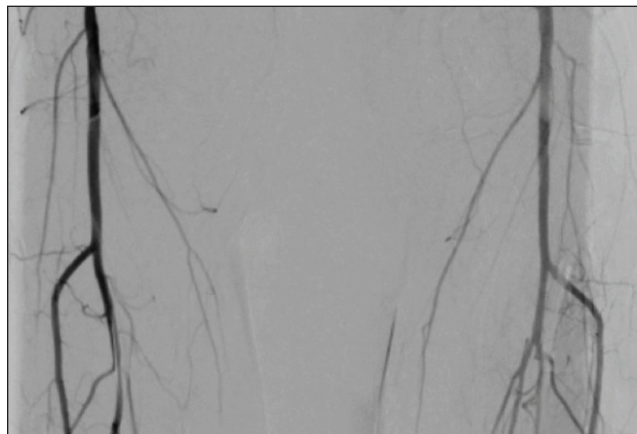


Figure 2. Runoff was normal in both lower extremities.

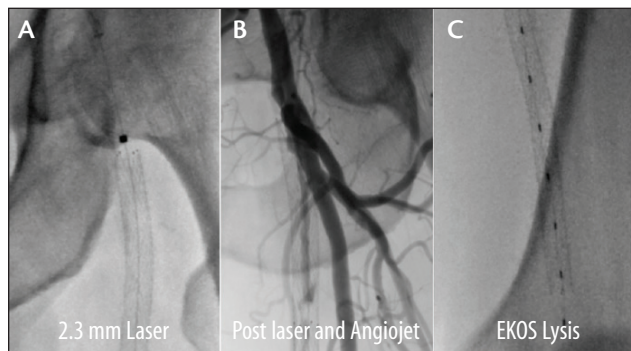


Figure 3. The left SFA was persistently occluded following laser atherectomy (A) and thrombectomy with the AngioJet Solent system (B), so EkoSonic thrombolysis with tenecteplase was initiated.

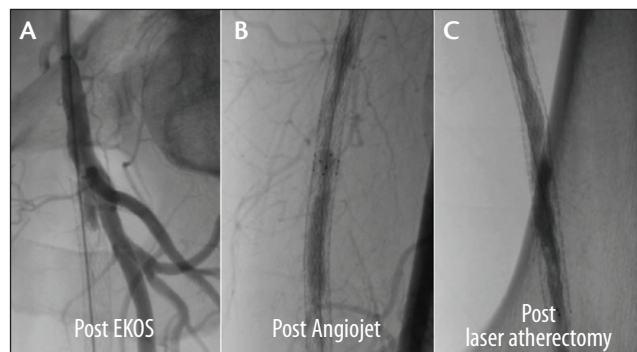


Figure 4. Angiogram following overnight EkoSonic thrombolysis with tenecteplase showed a persistent occlusion (A). Additional thrombectomy with the AngioJet Solent restored antegrade flow (B). Additional atherectomy debulking of the ISR tissue was then performed using laser atherectomy (C) before stent placement.

group company) (Figure 3C). The next day, repeat angiography after the overnight thrombolysis showed a persistent occlusion (Figure 4). This was treated with additional thrombectomy with the AngioJet Solent, laser atherectomy, followed by implantation of two 6-mm GORE VIABAHN Devices (Figure 5). Completion angiography revealed an excellent result with 0% to 10% residual stenosis throughout and no distal emboli. Based on the RELINE trial data and my clinical experience, the GORE VIABAHN Device is an excellent choice for treating long-segment de novo as well as in-stent restenotic occlusions. ■

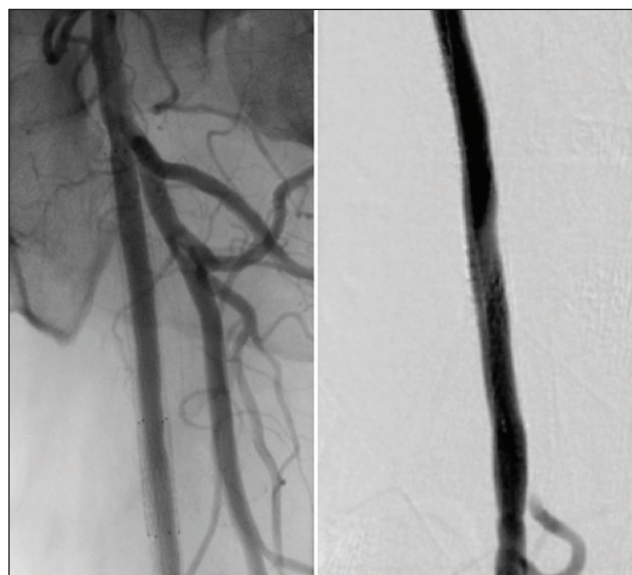

Figure 5. Final result after implantation of two 6-mm GORE VIABAHN Devices were placed.

*Robert M. Bersin, MD, FACC, FSCAI, is Medical Director of Endovascular Services and Medical Director of Structural Heart Services at Swedish Medical Center in Seattle, Washington. He has disclosed that he is a consultant to Medtronic, Spectranetics Corporation, and Gore & Associates. Dr. Bersin may be reached at robert.bersin@swedish.org.*

# Innovation Fueling Evolution: Two Decades of the GORE® VIABAHN® Endoprosthesis

Through the incorporation of technological advances, the contemporary GORE VIABAHN Device has evolved to offer robust treatment options to a diverse and growing population of patients with peripheral artery disease.

BY M. CASEY BECKER, MD, FACC, FSCAI, FSVM

Beginning with the European introduction of the original GORE® HEMOBAHN® Endoprosthesis in 1996 (Figure 1), the potential of “endovascular bypass” became apparent. Quickly following its United States introduction in 2002, the expanded polytetrafluoroethylene (ePTFE)-lined endoprosthesis was recognized as a potential treatment option for patients with complex superficial femoral artery disease.

## BUILDING UPON SUCCESSES OF THE PAST

After incorporating the now-familiar tip-to-hub deployment mechanism in the 6- to 8-mm-diameter devices in 2003, the US Food and Drug Administration (FDA) granted approval for superficial femoral artery implantation in 2005. The proprietary endoluminal CBAS® Heparin Surface—a bioactive, thromboresistant coating—was incorporated in 2007 with the intent to improve thromboresistance (Figure 2). In 2008, the FDA expanded the device’s indication to include iliac arteries, compatible with all device sizes.

A manufacturing change in 2009 allowed for laser con-

touring of the proximal edge, which impacted flow characteristics. That same year, Gore introduced 9- to 13-mm devices compatible with 0.035-inch guidewires. Given the advantages of a reduced crossing profile, 5- to 8-mm heparin-coated devices were offered in a configuration that reduced profile by one French size (0.014- or 0.018-inch guidewire compatible) in 2011, substantially increasing deliverability of the endoprosthesis while minimizing the introducer/sheath size.

The device’s proven clinical history in long SFA lesions prompted the development of the longest-length stent or stent-graft at 25 cm (Figure 3), and the FDA approved this device in late 2013. The 25-cm product offering aligns well with the results from the recent VIASTAR trial, where a substantial and statistically significant improvement in primary patency was observed compared to bare-metal stents in lesions ≥ 20 cm (73% vs 33% at 12 months;  $P = 0.004$ , per-protocol analysis).<sup>1</sup> The 25-cm GORE VIABAHN Device also offers operators cost-savings over using multiple devices, and may reduce procedural and radiation exposure time


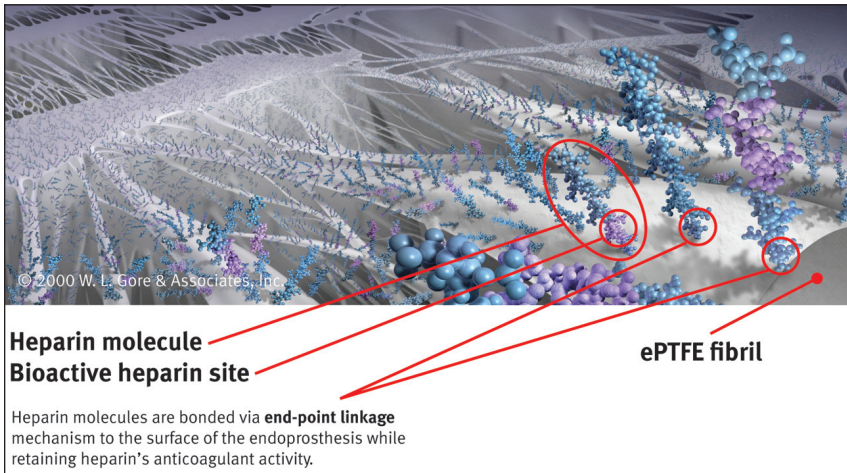


Figure 1. Evolution of the GORE VIABAHN Device over the past 20 years.




**Figure 2.** Schematic depicting the mechanism of endpoint covalent bonding (CBAS Heparin Surface) intended to provide thromboresistance via sustained endoluminal heparin bioactivity. Note that the heparin-active site catalytically facilitates antithrombin-thrombin complex formation and then becomes available to repeat the reaction.



**Figure 4.** Gold radiopaque markers recently added to the ends of 5- to 8-mm devices.

© 2014 W. L. Gore & Associates, Inc. Used with permission



**Figure 3.** The 25-cm GORE VIABAHN Device was approved in 2013.

with the benefits of single device deployment as opposed to overlapping shorter devices. That same year saw the FDA approval of the GORE VIABAHN Device for revision of arteriovenous access grafts in dialysis-dependent patients.

With a growing number of previously treated patients returning with in-stent restenosis, welcome data from the RELINE trial<sup>2</sup> supported FDA approval of the 5- to 7-mm GORE VIABAHN Devices for treatment of in-stent restenosis in September 2014. Most recently, all 5- to 8-mm devices have been fitted with radiopaque markers (Figure 4) that allow improved visualization of the device. This recent modification enhances the already high precision of deployment and facilitates visualization of the deployed device, particularly when treating in-stent restenosis.

**MEETING FUTURE CHALLENGES WITH TECHNOLOGY OF THE PRESENT**

The population of patients with peripheral artery disease continues to grow and become more complex. Simultaneously, the preference for endovascular therapies justifiably rises as well. The maturation rapidity of

armamentarium must keep pace with that of our skill-set. Success in this regard can only be achieved through vibrant, synergistic collaboration between physicians and industry leaders so innovation may fuel device evolution to meet the growing needs of our patients. ■

*M. Casey Becker, MD, FACC, FSCAI, FSVM, is with the Peripheral, Structural, and Coronary Interventional Therapies Division, Saint Vincent Heart and Vascular Institute; and is President and Founder of Panvascular Consulting LLC in Erie, Pennsylvania. He has disclosed that he has financial interests with Bard Peripheral Vascular, Edwards Lifesciences, CSI, Covidien, Medtronic, Spectranetics Corporation, Gore & Associates, ASZ, Janssen, and DSI. Dr. Becker may be reached at (814) 453-7767, ext. 2241; raydancase@yahoo.com; panvascularconsulting.com.*

1. Lammer J, Zeller T, Hausegger KA, et al. Heparin-bonded covered stents versus bare-metal stents for complex femoropopliteal artery lesions: the randomized VIASTAR trial (Viabahn endoprosthesis with PROPATEN bioactive surface [VIA] versus bare nitinol stent in the treatment of long lesions in superficial femoral artery occlusive disease). *J Am Coll Cardiol.* 2013;62:1320-1327.  
 2. Deloose K. RELINE - randomized clinical trial: Viabahn covered stents vs. PTA. Presented at The Leipzig Interventional Course - LINC 2014; January 28-31, 2014; Leipzig, Germany.

© 2014 W. L. Gore & Associates, Inc. Used with permission



# Optimal Technique for Use of the GORE® VIABAHN® Endoprosthesis

Best practices and treatment considerations for using stent-grafts.

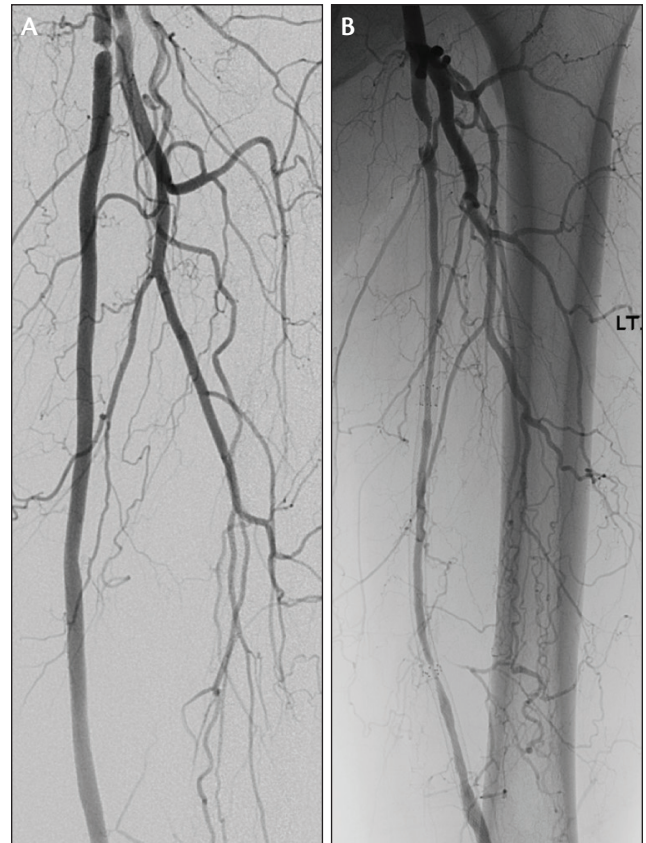
BY BARRY S. WEINSTOCK, MD, FACC

The GORE VIABAHN Device has been used for percutaneous management of long, complex femoropopliteal occlusive disease with favorable results, as demonstrated in numerous clinical trials. Factors favoring this approach include a length-independent restenosis rate, outstanding flexibility, and a reported fracture rate of < 0.015%.\* The GORE VIABAHN Device demonstrated significantly higher primary patency over bare-metal stents in the randomized VIASTAR trial (78% vs 54% at 12 months;  $P = 0.009$ , per-protocol analysis)<sup>1</sup> and has even shown long-term equivalence to expanded polytetrafluoroethylene (ePTFE) bypass graft surgery.<sup>2</sup> Recent trials such as the Gore VIPER clinical study have demonstrated exceptional outcomes using the GORE VIABAHN Device with CBAS® Heparin Surface and have shed light on factors that optimize outcomes.

Translating the results seen in clinical trials to clinical practice may be more challenging for stent-grafts than for bare-metal stents. Technical considerations are of greater importance and significantly impact procedural outcomes. The predominant failure mechanism for the GORE VIABAHN Device is edge restenosis, which, if left untreated, can lead to stent-graft thrombosis resulting in total occlusion. Conversely, bare-metal stents more commonly develop diffuse restenosis due to neointimal hyperplasia, which ultimately may result in stent occlusion as well (Figure 1).

## TECHNICAL CONSIDERATIONS

Despite the device improvements noted in this supplement's article by Dr. Becker, "Innovation Fueling Evolution: Two Decades of the GORE® VIABAHN® Endoprosthesis" (see page 15), the most critical elements of successful GORE VIABAHN Device usage remain related to technique. Perhaps the most important lesson from clinical trials relates to **proper sizing of the GORE VIABAHN Device**. Although it is common in clinical practice to oversize bare-metal self-expanding stents by 1 to 2 mm, it is clear that oversizing GORE VIABAHN Devices by more than 20% of the vessel diameter leads to significantly lower patency rates (Figure 2).<sup>3</sup> The operator should also pay attention to the distal vessel, where the vessel diameter is often smaller than in the proximal vessel. For long segments of disease requiring overlapping stents, the GORE VIABAHN Devices may be "telescoped," perhaps utilizing a 5-mm-diameter stent-graft



Courtesy of Peter Soudas, MD.

Figure 1. Patterns of SFA restenosis. The GORE VIABAHN Device showing focal proximal edge stenosis (A) and bare-metal stents showing diffuse long-segment restenosis (B).

followed by deployment of a 6-mm device more proximally in overlapping fashion. The resulting "tapered" stent-graft will match both the proximal and distal vessel diameters appropriately without oversizing distally or undersizing proximally. When utilizing the GORE VIABAHN Device for treatment of in-stent restenosis, the stent-graft should be sized based on the diameter of the normal vessel proximal and distal to the bare-metal stent, not based on the size of the implanted stent.

It is also essential to treat all of the disease with the GORE VIABAHN Device, from "normal to normal." As a corollary to this axiom, if the device is to be deployed in the proximal superficial femoral artery (SFA), it is preferable

© 2015 W. L. Gore & Associates, Inc. Used with permission.

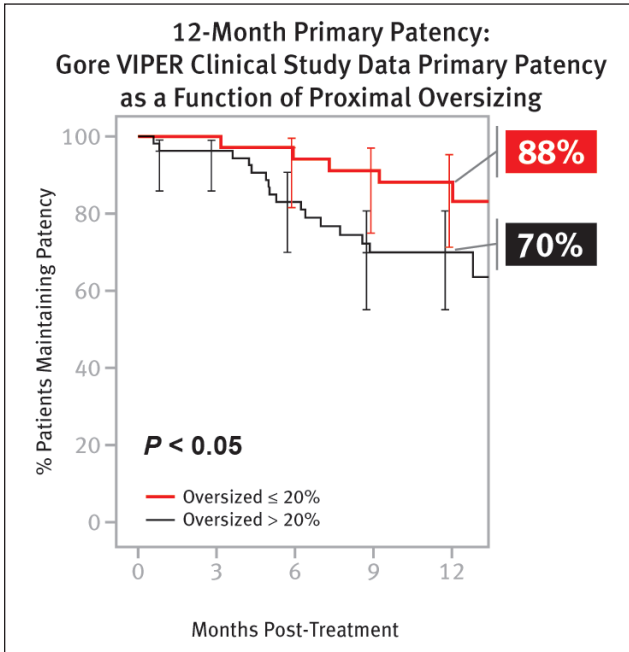


Figure 2. The Gore VIPER study showed lower restenosis rates for the GORE VIABAHN Device with ≤ 20% oversizing versus those with > 20% oversizing, as assessed by an independent core lab.

to cover all the way back to the true ostium of the SFA, which can be clearly identified using an ipsilateral angulated view of 30° to 45°. Importantly, it is sometimes necessary to cover a collateral to the distal SFA in order to stent from “normal to normal.” Although some operators are reluctant to cover collaterals, the recent Gore VIPER clinical study demonstrated that the risk of acute limb ischemia from GORE VIABAHN Device thrombosis is rare (1%),<sup>3</sup> and the VIASTAR randomized trial demonstrated no significant difference in the incidence of acute limb ischemia with the GORE VIABAHN Device versus bare-metal stents ( $P = 1.0$ ).<sup>1</sup> Failure to stent distally enough to reach a normal segment due to fear of covering a collateral is an avoidable technical mistake that may compromise long-term patency.

As it is commonly necessary to overlap GORE VIABAHN stents due to the long lesion lengths that are often treated, care should be taken to overlap the stents by at least 1 cm. It is also important to postdilate the GORE VIABAHN Device(s) using moderate- to high-pressure balloon angioplasty inflations. When postdilating, the balloon should not be allowed to extend past the edge of the GORE VIABAHN Device. Clear knowledge of the angioplasty balloon’s shoulders and their relationship to the balloon’s radiopaque markers is essential. If uncertain, it is best to dilate 1 cm inside the edge of the GORE VIABAHN Device initially to visualize those factors before dilating more precisely at the edge. Dilating outside the stent-graft edges may lead to edge dissections and/or an

**TOP 10 TECHNICAL CONSIDERATIONS FOR UTILIZING THE GORE VIABAHN DEVICE**

1. Avoid excessive oversizing (> 20%)
2. Ensure adequate inflow and outflow
3. Treat all of the disease (stent “normal to normal”)
4. Regular duplex ultrasonography follow-up
5. Prescribe appropriate antiplatelet therapy
6. Postdilate
7. Do not use PTA outside of the device
8. Treat progressing disease
9. Place device at the SFA origin if proximal SFA disease is present
10. Overlap devices by at least 1 cm

increased restenosis rate typical of balloon angioplasty and is to be avoided.

Ideally, there should be at least one patent infrapopliteal run-off vessel free of significant stenosis. If necessary, intervention may be required to optimize the distal run-off in order to enhance GORE VIABAHN Device patency. Similarly, if there is significant inflow (iliac) disease, this should be treated before deploying GORE VIABAHN Devices in the femoropopliteal circulation; iliac intervention during the same procedure is reasonable.

**POSTPROCEDURE MANAGEMENT**

Postprocedure management is critical for long-term success. Although some investigators have recommended **dual antiplatelet therapy (DAPT)** (typically aspirin and clopidogrel) for as little as 6 weeks, most experienced operators have found results to be optimal with long-term, if not indefinite, antiplatelet therapy. At a minimum, 1 year of DAPT should be utilized if possible.

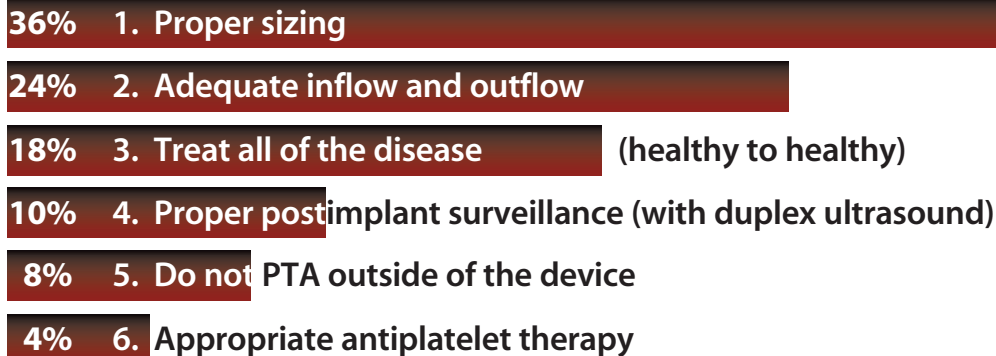
**Routine duplex ultrasonography** is critically important to monitor for edge restenosis, especially during the first year, in order to minimize the risk of GORE VIABAHN Device failure (thrombosis).<sup>4</sup> Although there are no published guidelines, consensus opinion favors duplex ultrasonography every 3 to 4 months during the first year, followed by every 6 months thereafter. After 3 years, annual surveillance ultrasonography is reasonable.

**MANAGEMENT OF RESTENOSIS/THROMBOSIS**

Unlike bare-metal stent restenosis, which often is diffuse, GORE VIABAHN Device edge restenosis is focal and is often asymptomatic and associated with a normal or nearly normal ankle-brachial index. Nonetheless, it is necessary to treat hemodynamically significant edge restenosis to avoid slow flow and the inevitable thrombosis. A peak systolic velocity of ≥ 250 to 300 cm/sec or a PSVR > 2.5

## ASK THE EXPERTS

## In order of primacy, which three of these technical considerations is most important to you when utilizing the GORE VIABAHN Device?



should prompt interventional management of edge restenosis, typically with balloon angioplasty and an “extension” using a 5-cm-long stent of the same diameter as the prior stent-graft. Many clinicians prefer a cutting or scoring balloon before placing the GORE VIABAHN Device extension, although there are no data to support this approach. Finally, if new disease develops proximal or distal to the treated segment, it should be aggressively treated using similar criteria for edge restenosis.

In rare instances, patients may develop GORE VIABAHN Device thrombosis. The majority of these patients present with symptoms that are similar (if not less severe) to their initial presentation, rather than as acute limb ischemia.<sup>5</sup> For patients with acute limb ischemia, antegrade flow must be restored rapidly, which is possible using rheolytic thrombectomy devices such as the AngioJet™ Thrombectomy System (Boston Scientific Corporation), particularly when used with a power-pulse spray technique with thrombolytic therapy (eg, tissue plasminogen activator). It may be helpful to place a distal protection filter to reduce the risk of distal embolization.

For patients with recurrent claudication, flow may be restored using thrombolysis. Ultrasound-assisted thrombolysis utilizing the EkoSonic® System (Ekos Corporation, a BTG International group company) provides a quick, simple approach. The thrombotic occlusion is crossed, and the EKOS catheter is placed. Thrombolytic therapy is administered for 8 to 24 hours, which typically resolves all of the thrombus without any embolization. The patient can then be returned to the laboratory for treatment of the residual edge stenosis that may be present at the proximal edge, distal edge, or occasionally, at both edges.

### CONCLUSION

The GORE VIABAHN Device provides an attractive treatment option for long, complex lesions, including chronic total occlusions in the femoropopliteal artery. Favorable graft characteristics include flexibility, fracture resistance, and a low length-independent restenosis rate. Recent clinical trials have demonstrated the potential benefits of the GORE VIABAHN Device in extremely challenging lesion subsets. Moreover, those same trials have illuminated the critical importance of utilizing proper technique in order to achieve optimal results. By following the best practices discussed here, endovascular bypass utilizing the GORE VIABAHN Device can be an invaluable tool in the peripheral vascular interventional armamentarium. ■

*Barry S. Weinstock, MD, FACC, is with Florida Heart & Vascular Center in Leesburg, Florida. He has disclosed that he is a consultant and on the speakers' bureau for Gore & Associates. Dr. Weinstock may be reached at (407) 948-0535; bweinstock@me.com.*

\*Data on file.

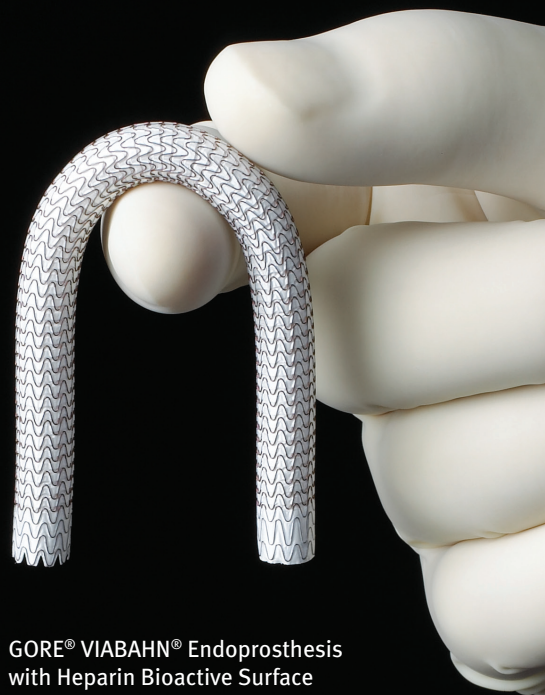1. Lammer J, Zeller T, Hausegger KA, et al. Heparin-bonded covered stents versus bare-metal stents for complex femoropopliteal artery lesions: the randomized VIABAHN trial (Viabahn endoprosthesis with PROPATEN bioactive surface [VIA] versus bare nitinol stent in the treatment of long lesions in superficial femoral artery occlusive disease). *J Am Coll Cardiol*. 2013;62:1320-1327.
2. McQuade K, Gable D, Pearl G, et al. Four-year randomized prospective comparison of percutaneous ePTFE/nitinol self-expanding stent graft versus prosthetic femoral-popliteal bypass in the treatment of superficial femoral artery occlusive disease. *J Vasc Surg*. 2010;52:584-590; discussion 590-591.
3. Saxon RR, Chervu A, Jones PA, et al. Heparin-bonded, expanded polytetrafluoroethylene-lined stent graft in the treatment of femoropopliteal artery disease: 1-year results of the VIPER (Viabahn Endoprosthesis with Heparin Bioactive Surface in the Treatment of Superficial Femoral Artery Obstructive Disease) trial. *J Vasc Interv Radiol*. 2013;24:165-173.
4. Scali ST, Beck AW, Nolan BW, et al. Completion duplex ultrasound predicts early graft thrombosis after crural bypass in patients with critical limb ischemia. *J Vasc Surg*. 2011;54:1006-1010.
5. Lensvelt MM, Golchehr B, Kruse RR, et al. The outcome of failed endografts inserted for superficial femoral artery occlusive disease. *J Vasc Surg*. 2013;57:415-420.

# No Device is Proven Better for Complex In-stent Restenosis Lesions.<sup>1-3</sup>

**75%** Primary Patency  
at 12 Months<sup>4</sup>

**17.3 cm** Mean  
Lesion Length

**80%** fTLR at  
12 Months



GORE® VIABAHN® Endoprosthesis  
with Heparin Bioactive Surface


## The GORE® VIABAHN® Endoprosthesis has been approved as a safe, effective treatment for in-stent restenosis.<sup>1</sup>

<sup>1</sup> Bosiers M, Deloosse K, Callaert J, et al. Superiority of stent-grafts for in-stent restenosis in the superficial femoral artery: twelve month results from a multicenter randomized trial. *Journal of Endovascular Therapy* 2015;22(1):1-10.

<sup>2</sup> Krankenberg H; on behalf of the FAIR Trial Investigators. DCB and ISR: Insights from the FAIR Study. Presented at the Leipzig Interventional Course (LINC); January 27-29, 2015; Leipzig, Germany.

<sup>3</sup> Dippel EJ; EXCITE ISR Investigators. EXCITE ISR: initial results. Presented at the Transcatheter Cardiovascular Therapeutics Twenty-Sixth Annual Symposium Transcatheter Cardiovascular Therapeutics (TCT); September 13-17, 2014; Washington, DC.

<sup>4</sup> Deloosse K. RELINE - randomized clinical trial: Viabahn covered stents vs. PTA. Presented at The Leipzig Interventional Course (LINC) 2014; January 28-31, 2014; Leipzig, Germany.

**INTENDED USE / INDICATIONS:** The GORE® VIABAHN® Endoprosthesis is indicated for improving blood flow in patients with symptomatic peripheral arterial disease in superficial femoral artery de novo and restenotic lesions up to 270 mm in length with reference vessel diameters ranging from 4.0 – 7.5 mm, in superficial femoral artery in-stent restenotic lesions up to 270 mm in length with reference vessel diameters ranging from 4.0 – 6.5 mm, and in iliac artery lesions up to 80 mm in length with reference vessel diameters ranging from 4.0 – 12 mm. The GORE® VIABAHN® Endoprosthesis is also indicated for the treatment of stenosis or thrombotic occlusion at the venous anastomosis of synthetic arteriovenous (AV) access grafts. Refer to *Instructions for Use* at [goremedical.com](http://goremedical.com) for a complete description of all contraindications, warnings, precautions and adverse events. 

W. L. Gore & Associates, Inc. • Flagstaff, AZ 86004 • [goremedical.com](http://goremedical.com)

Products listed may not be available in all markets.

GORE®, HEMOBAHN®, PERFORMANCE THROUGH INNOVATION, VIABAHN®, and designs are trademarks of W. L. Gore & Associates. CARMEDA® and CBAS® are trademarks of Carmeda AB, a wholly owned subsidiary of W. L. Gore & Associates. All other trademarks are the property of their respective owners.

© 2015 W. L. Gore & Associates, Inc. AU0216-EN1 JUNE 2015



HEPARIN  
BIOACTIVE SURFACE

PERFORMANCE  
through innovation