

TREATING CLAUDICATION AND REST PAIN DUE TO CHRONIC TOTAL OCCLUSION OF THE SFA

Case submitted by James Otto, M.D.

Challenge

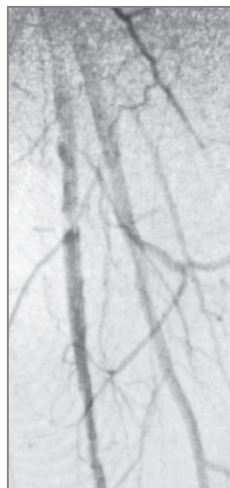
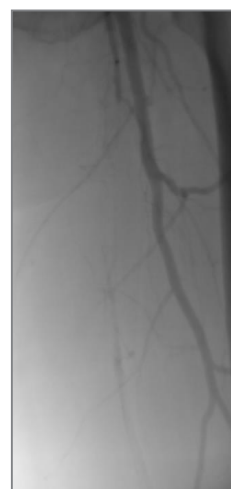
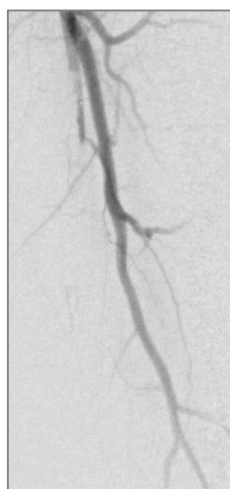
Treatment of a patient with total occlusion of the superficial femoral artery (SFA)

- 65-year-old woman presented with severe peripheral arterial disease, claudication and rest pain of left lower extremity.
- Angiography revealed total occlusion of the left SFA.

Procedure

Endoluminal bypass performed with the VIABAHN® Device

- Obtained percutaneous access into the right femoral artery with ultrasound guidance. Then performed an angiogram of the left lower extremity.
- Crossed SFA chronic total occlusion (CTO) with 035 TERUMO® RADIFOCUS® GLIDEWIRE® ADVANTAGE Guidewire and 035 TEURMO® NAVICROSS® Support Catheter.
- Atherectomy completed with CARDIOVASCULAR SYSTEMS DIAMONDBACK 360® Peripheral Orbital Atherectomy System 2.0 Solid Crown.
- Followed by angioplasty with a 5 mm percutaneous transluminal angioplasty (PTA) balloon.
- Deployed two 6 mm x 15 cm VIABAHN® Devices in the SFA and post-dilated with 6 mm PTA balloon.

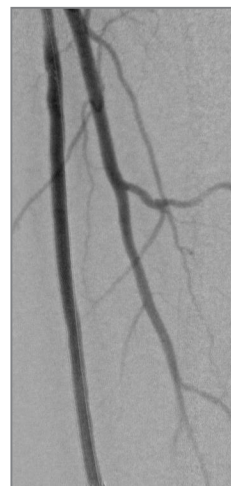

* As used by Gore, PROPATEN Bioactive Surface refers to Gore's proprietary CBAS Heparin Surface.

Result

The VIABAHN® Device restored blood flow in the SFA

- Completion angiogram showed excellent flow of the left lower extremity. Immediately post-op, complete resolution of left sided severe claudication.
- At follow-up office visit 2.5 weeks post-op, the patient presented with complete resolution of claudication and rest pain. Patient had palpable tibial pulses bilaterally.



Case Takeaway

As demonstrated in this case, the VIABAHN® Device offers excellent patency in the treatment of long SFA total occlusions and should be considered first-line treatment for complex SFA disease.

The VIABAHN® Device has demonstrated durability and long-term patency in the treatment of complex SFA disease with 97% three-year secondary patency (27 cm average lesion length, 93% CTOs).¹

Images courtesy of James Otto, M.D. Used with permission.

1. Böhme T, Noory E, Brechtel K, *et al.* Heparin-bonded stent-graft for the treatment of TASC II C and D femoropopliteal lesions: 36-month results of the Viabahn 25 cm Trial. *Journal of Endovascular Therapy*. In press.

 Consult Instructions
for Use
eifu.goremedical.com

Refer to *Instructions for Use* at eifu.goremedical.com for a complete description of all applicable indications, warnings, precautions and contraindications for the markets where this product is available. Rx Only

This content is for informational purposes only, is not advice or a guarantee of outcome. It is not a substitute for professional medical advice, diagnosis or treatment. Individual results and/or treatment may vary based upon the circumstances, the patient's specific situation, and the healthcare provider's medical judgment.

Products listed may not be available in all markets.

CARDIOVASCULAR SYSTEMS and DIAMONDBACK 360 are trademarks of Cardiovascular Systems, Inc.
TERUMO, NAVICROSS and RADIFOCUS GLIDEWIRE are trademarks of Terumo Medical Corporation.
GORE, *Together, improving life*, VIABAHN and designs are trademarks of W. L. Gore & Associates.
© 2021 W. L. Gore & Associates, Inc. 2158794-EN MARCH 2021

W. L. Gore & Associates, Inc.
goremedical.com

Asia Pacific +65 67332882 Australia/New Zealand 1800 680 424 Europe 00800 6334 4673
United States Flagstaff, AZ 86004 800 437 8181 928 779 2771

